



# CASE REPORT

## Neurocysticercosis

Andrew H. Kerstein, D.O.<sup>1</sup>

Andrew D. Massey, M.D.<sup>2</sup>

University of Kansas School of Medicine-Wichita

<sup>1</sup>Department of Psychiatry and Behavioral Sciences

<sup>2</sup>Department of Internal Medicine

### Introduction

Cysticercosis is caused by the larval stage of *Taenia solium* (*T. solium*).<sup>1</sup> Clinical syndromes related to this parasite are divided into neurocysticercosis (NCC) and extraneural cysticercosis (ECC). NCC, in turn, is divided into parenchymal and extraparenchymal forms. Tissue cysticerci develop from oncospheres, which are invasive larvae transformed from *Taenia* eggs, over a period of three to eight weeks following ingestion of *T. solium*. Cysticerci typically remain in this stage for many years.

The *Taenia* species has a number of very sophisticated mechanisms to evade destruction by the human body including production of serine proteases. Symptoms develop when the body eventually attacks the cyst and kills it. In general, parenchymal cysts are associated with seizures and headache, while extraparenchymal cysts are associated with symptoms of elevated intracranial pressure (e.g., headache, nausea, and vomiting) and may be accompanied by altered mental status.

Neurocysticercosis is a leading cause of seizures in developing countries. Persons with a history of living in or traveling to endemic areas or those living in close association to persons known to have cysticercosis deserve further evaluation of this as an etiology of a seizure or psychiatric disorder. Limited study exists on neuropsychiatric manifestations. However, there

appears to be high psychiatric morbidity in untreated cases.

### Case Report

A 44-year-old, right-handed, employed, married, Hispanic, solely Spanish speaking male presented to the emergency room of a community hospital with a headache and seizure-like activity. The patient had intermittent headaches over the past two years, but they had become more frequent in recent weeks. On the day of presentation to the emergency room, the patient developed a severe headache that atypically did not resolve. He attributed the headache to paint fumes he inhaled while painting his house that day. Over the course of the day, his wife noted that he was having difficulty finding words, was increasingly somnolent, and confused. He experienced two generalized tonic clonic seizures later that day, each lasting 60 to 90 seconds, and was transported to the local emergency room. Subsequently, he was transferred to a regional medical center for further evaluation.

The patient's medical history was notable for gout, appendectomy, cholecystectomy, and vasectomy. His family history included diabetes mellitus and hypertension. He was employed at a chicken and beef processing facility in Western Kansas. He had no tobacco, alcohol, or illicit drug use history. The

patient was born and lived in Mexico before moving to the United States about 10 years prior to presentation. He last visited Mexico during the summer less than two years before presentation.

The presenting vital signs included temperature of 97.2° F, pulse of 80 bpm, blood pressure of 110/60 mmHg, height of 5'9", and weight of 99.7 kg. His Mini-Mental State Examination revealed mild cognitive impairment with a score of 23. He had difficulty concentrating and was unable to spell the Spanish equivalent of "world" backwards. His visual fields were full and central visual acuity was 20/20 OU. Strength and tone in upper and lower extremities were normal. Coordination and fine motor movements were normal. Vibratory and cold sensation and two-point discrimination were normal. His tendon reflexes were not brisk and his plantar responses were flexor.

All blood and urine tests were normal. The cysticercosis IgG antibody was negative. HIV, Strongyloides antibody, TSH, and TB tests were normal. A skeletal

x-ray and electroencephalogram were normal. Magnetic resonance imaging of the brain, with and without contrast, revealed a 19.5 mm x 12.5 mm x 16.5 mm left posterior temporal cyst with small nodule (see Figures 1a and 1b). Vasogenic edema was noted with the margins measuring approximately 3 cm in average diameter. The characteristics of the lesion suggested cysticercosis. A diagnosis of neurocysticercosis was made. The patient's history of being from an endemic area, exposure to poor sanitation, and the characteristics of the clinical presentation helped form the diagnosis.

Initially, the patient was given IV dexamethasone and loaded with fosphenytoin because of the seizure episodes and brain edema. His mental status rapidly improved. He was discharged from the hospital after three days. He was given a course of albendazole and an oral prednisone taper upon hospital discharge. He was scheduled for a repeat MRI two months later and was followed by an infectious disease specialist.

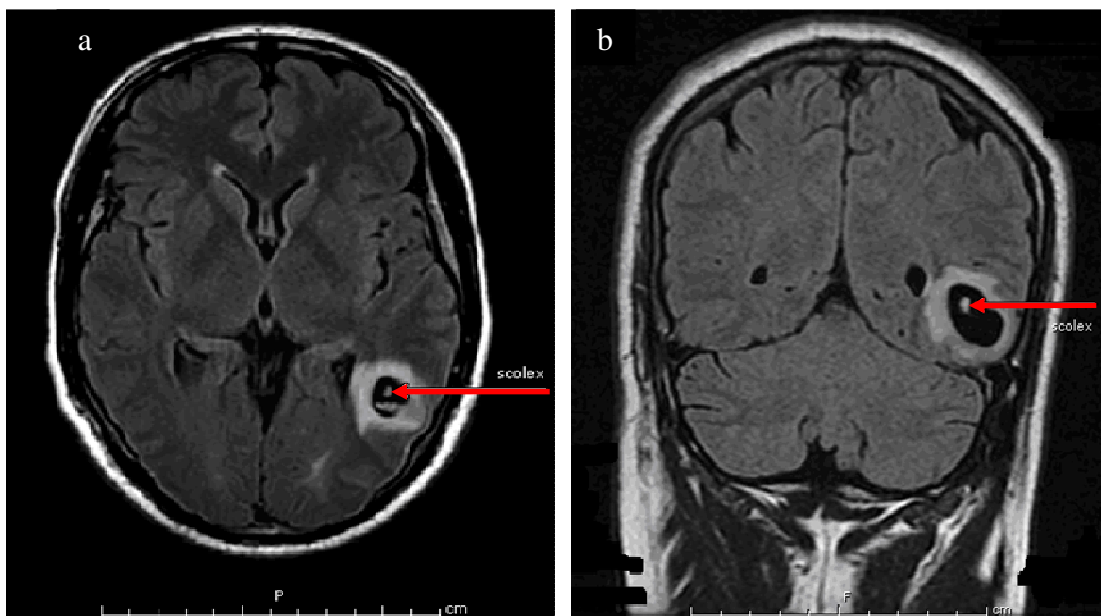


Figure 1. MRI on day of admission. Red arrows note the scolex visible in the cyst.

## Discussion

The life cycle of *T. solium*, the tapeworm causing NCC, is complicated and humans are a dead end host with swine as an intermediate host.<sup>2</sup> Poor sanitary conditions in developing countries have been the environment characterized as where the species is endemic, however, that need not be the case. Individuals with no history of pork consumption or travel to endemic areas also can develop NCC. In a report of four cases in an Orthodox Jewish community (whose dietary laws strictly prohibit consumption of pork), infection was transmitted by domestic workers who recently had emigrated from Latin American countries where *T. solium* is endemic.<sup>3</sup>

Pharmaceutical treatments for cysticercosis are most commonly albendazole and praziquantel.<sup>4</sup> Albendazole (15 mg/kg per day ~ 800 mg/day in two divided doses) facilitates the destruction of parenchymal cysticerci. Praziquantel (50 to 100 mg/kg per day in three divided doses) is an alternative to albendazole, but also is used in cases of infection in the gastrointestinal tract and elsewhere aside from the central nervous system.

Psychiatric manifestations have been recognized as depression, psychosis, and cognitive decline.<sup>5</sup> Psychosis may be seen in up to 5% of patients.<sup>6</sup> In a series of studies conducted in Brazil, psychiatric disorders occurred in 65.8%, evidence of cognitive decline in 87.5%, depression in 52.6%, and psychosis in 14.2% of patients.<sup>7</sup>

A point of medical and public health interest is that cysticercosis and neurocysticercosis are not reportable diseases in Kansas or most other states. This case may serve as encouragement for authorities to reconsider the importance of this disease to be added to the list of reportable diseases.

## References

- <sup>1</sup> White AC Jr. Clinical manifestations and diagnosis of cysticercosis. January 2010. Accessed at: <http://www.utdol.com>.
- <sup>2</sup> Cook GC, Zumla AI. Manson's Tropical Diseases. 21st Edition. Oxford: W.B. Saunders, 2003.
- <sup>3</sup> Schantz PM, Moore AC, Munoz JL, et al. Neurocysticercosis in an Orthodox Jewish community in New York City. N Engl J Med 1992; 327:692-695.
- <sup>4</sup> White AC Jr. Treatment of cysticercosis. January 2010. Accessed at: <http://www.utdol.com>.
- <sup>5</sup> Levenson JA. Textbook of Psychosomatic Medicine. Washington, DC: American Psychiatric Publishing, 2005.
- <sup>6</sup> Mahajan SK, Machhan PC, Sood BR, et al. Neurocysticercosis presenting with psychosis. J Assoc Physicians India 2004; 52:663-665.
- <sup>7</sup> Forlenza OV, Filho AH, Nobrega JP, et al. Psychiatric manifestations of neurocysticercosis: A study of 38 patients from a neurology clinic in Brazil. J Neurol Neurosurg Psychiatry 1997; 62:612-616.

*Keywords:* neurocysticercosis, cysticercosis, taenia solium, psychiatry, case report