

Rose Handler's Knee: A Case of Osteoarticular Sporotrichosis

Heather McWilliams DO¹, Nivedita Ganguly MD²

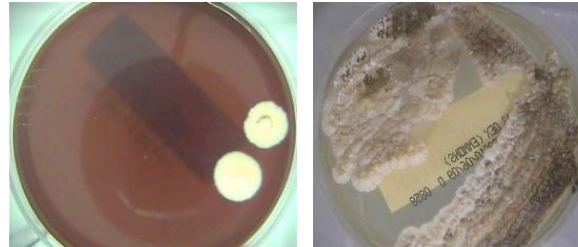
¹Department of Internal Medicine, ² Division of Infectious Diseases, University of Kansas Medical Center, Kansas City, KS

BACKGROUND

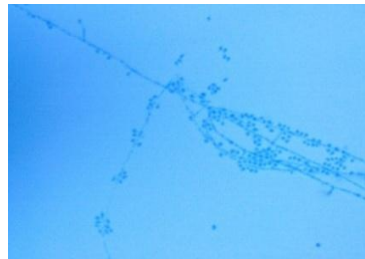Sporotrichosis, also known as "Rose Handler's Disease", is caused by the dimorphic fungus *Sporothrix schenckii*. It is found throughout the world in decaying vegetation, wood, sphagnum moss and soil. Typically, healthy adults acquire this disease by direct inoculation of skin during outdoor activities. Most commonly it presents as subacute or chronic lymphocutaneous lesions of the extremities. Hematogenous dissemination may result in unusual presentations including pulmonary, meningeal and osteoarticular disease. Extracutaneous manifestations are uncommon and most often reported in immunocompromised hosts in association with alcoholism, diabetes, COPD and AIDS.

CASE PRESENTATION

A 45 year old alcoholic male presented with worsening right knee pain, swelling and intermittent purulent drainage for several months. He had experienced a minor soft tissue injury of his right knee involving a chainsaw five years prior and an injury during a basketball game three years prior. In the past one year, he had multiple I&D procedures with negative cultures. He received multiple courses of oral and intravenous antibiotic regimens without improvement. His most recent I&D procedure was performed with placement of an antibiotic cement spacer with no improvement. Extensive bony destruction, purulence and a clear sinus tract were noted during this surgery. Finally, intraoperative tissue and bone cultures grew *Sporothrix schenckii* after a thirty day incubation period. Therapy was started with liposomal Amphotericin B, followed by oral Itraconazole with a plan to treat for at least one year in anticipation of knee replacement due to extensive bony destruction.



Colonies of *Sporothrix schenckii* from surgical specimen of this patient



Lactophenol cotton blue stain from the above colony: *Sporothrix schenckii*

REFERENCES

- Kauffman CA, Bustamante B, Chapman SW, Pappas PG. Clinical Practice Guidelines for the Management of Sporotrichosis: 2007 Update by the Infectious Diseases Society of America. *Clin Infect Dis* 2007; 45:1255-1265.
- Araujo TD, Marques AC, Kerdel F. Review Sporotrichosis. *International Journal of Dermatology* 2001;40:737-742.
- Campos-Macias P, Arenas R, Vega-Memije ME, Kawasaki, M. *Journal of Dermatology* 2006;33:295-299.
- Kaufman, C. Clinical features and diagnosis of sporotrichosis. *Basic Biology and Epidemiology of Sporotrichosis*. UptoDate.
- Long SS, Pickering LK, Prober CG, et al. *Principles and Practices of Pediatric Infectious Disease*. 3rd ed. Philadelphia, Pennsylvania: Elsevier Inc.; 2008 1193-1194.

DISCUSSION

Osteoarticular sporotrichosis causing septic arthritis and osteomyelitis is not a common presentation. It often involves a single joint such as the knee, elbow, ankle or wrist. A high index of suspicion should remain for *Sporothrix schenckii* when there is a history of injury involving possible soil inoculation, negative bacterial cultures and antibiotic treatment failure. Generally the outcome of osteoarticular sporotrichosis is poor due to delay in diagnosis and initiation of antifungal therapy. Diagnosis is often delayed by several months. This disease is difficult to treat with a high recurrence rate and poor outcome even after prolonged antifungal therapy.

DIAGNOSTIC TESTS

Culture is the gold standard for diagnosis of *Sporothrix Schenckii*. Material from cutaneous lesions, sputum, synovial fluid, CSF or biopsy should be obtained depending on location of infection. A majority of cases will show growth within eight days, however, some cases may take up to four weeks.

TREATMENT

First line treatment is Itraconazole 200mg orally twice daily for a minimum of twelve months. Amphotericin B is indicated for more severe cases. Ketoconazole and fluconazole have not been shown to be effective. Surgical debridement alone for osteoarticular sporotrichosis is not effective but often needed in addition to antifungal treatment.