

Subarachnoid Hemorrhage: Not Always A Simple Aneurysm

Amanda Waltner, MD and Andrew Massey, MD

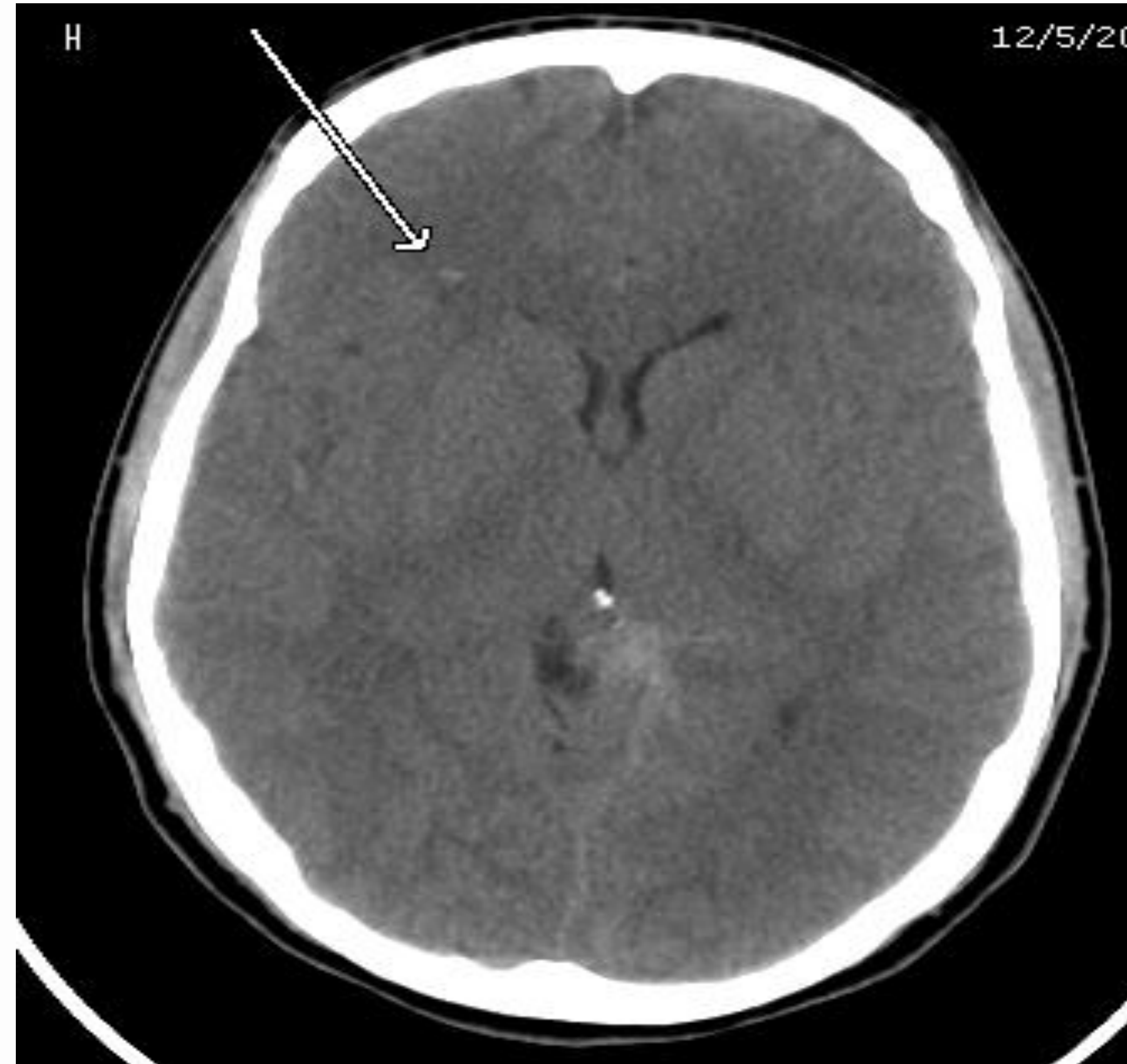Introduction

Subarachnoid hemorrhage (SAH) is a devastating condition. It occurs in 25/100,000 people yearly and is associated with a 51% mortality. Most commonly it is caused by saccular aneurysms. It is imperative that inquiry is made for other causes of SAH, especially in those who are young and without traditional risk factors.

Case History

A 24-year-old Caucasian male presented to the ED with headache for the past two weeks not relieved with acetaminophen plus codeine. He had no neurological deficit or other abnormalities. CT of the head revealed a left cerebral SAH without shift and petechial hemorrhage in the right frontal lobe. Labs were significant for hyponatremia and hypokalemia, and high leukocyte count.

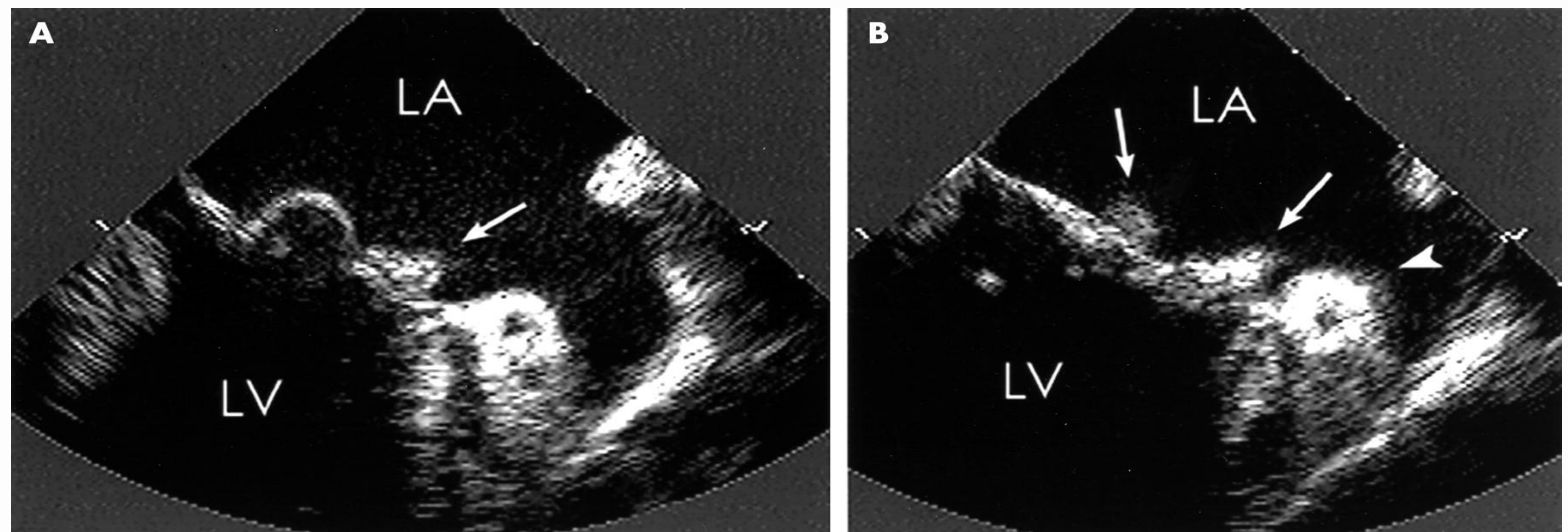
On day #3 of admission, he developed acute respiratory failure, requiring intubation, and decreased consciousness and confusion. Chest x-ray displayed pulmonary edema. There was a 4/6 systolic murmur on cardiac exam. Echocardiogram revealed a mitral vegetation with severe holo-systolic insufficiency. Blood cultures were positive for Group B Streptococcus. Thus it seems most likely that the patient developed a mycotic aneurysm from septic emboli resulting in his SAH. He was started on IV antibiotics and received an artificial valve. He did well post-op and was discharged to home in fair condition.



CT scan depicts the patient's left cerebral SAH and right petechial hemorrhage (arrow).

Discussion

Mycotic aneurysms account for less than 1% of all SAH. Approximately 20% of these aneurysms are secondary to endocarditis, though prior to antibiotics this was much higher. Most commonly, they are caused by infections with staphylococcus aureus. Fortunately, SAH secondary to these have a mortality of only 25% when treated with surgery and appropriate antibiotics. **While mycotic aneurysms are rare, identification of them in a timely fashion is imperative for the patient to receive appropriate treatment to decrease mortality.**



Echocardiogram with severe mitral vegetation (arrows).

References

1. Benderson JB, et al. Guidelines for the management of aneurysmal subarachnoid hemorrhage: a statement for healthcare professionals from a special writing group of the Stroke Council. Stroke 2009; 40:994-1025.
2. Peters PJ, et al. A dangerous dilemma: Management of infectious intracranial aneurysms complicating endocarditis. Lancet Infectious Disease 2006; 6:742.
3. Schwartz TH, Solomon RA. Perimesencephalic nonaneurysmal subarachnoid hemorrhage: Review of literature. Neurosurgery 1996; 39:433.
4. Shaikholeslami R, Tomlinson CS et al. Mycotic aneurysm complicating staphylococcal endocarditis. Canadian Journal of Cardiology 1999;47:193.