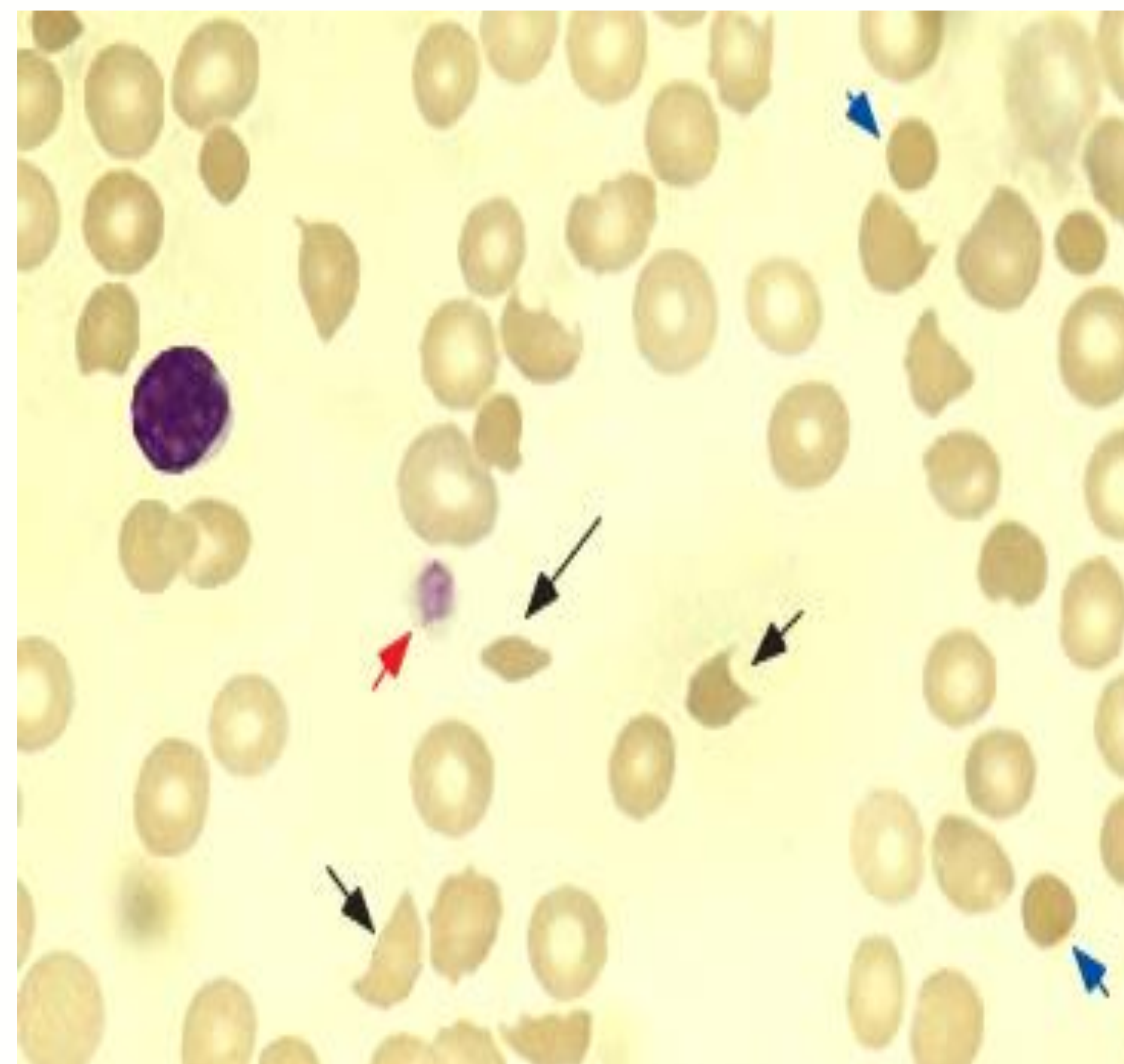


Thrombotic Thrombocytopenia Purpura Without Anemia: An Unusual Presentation

Aisha Aman, MD, Nassim Nabbout, MD, FACP

Introduction

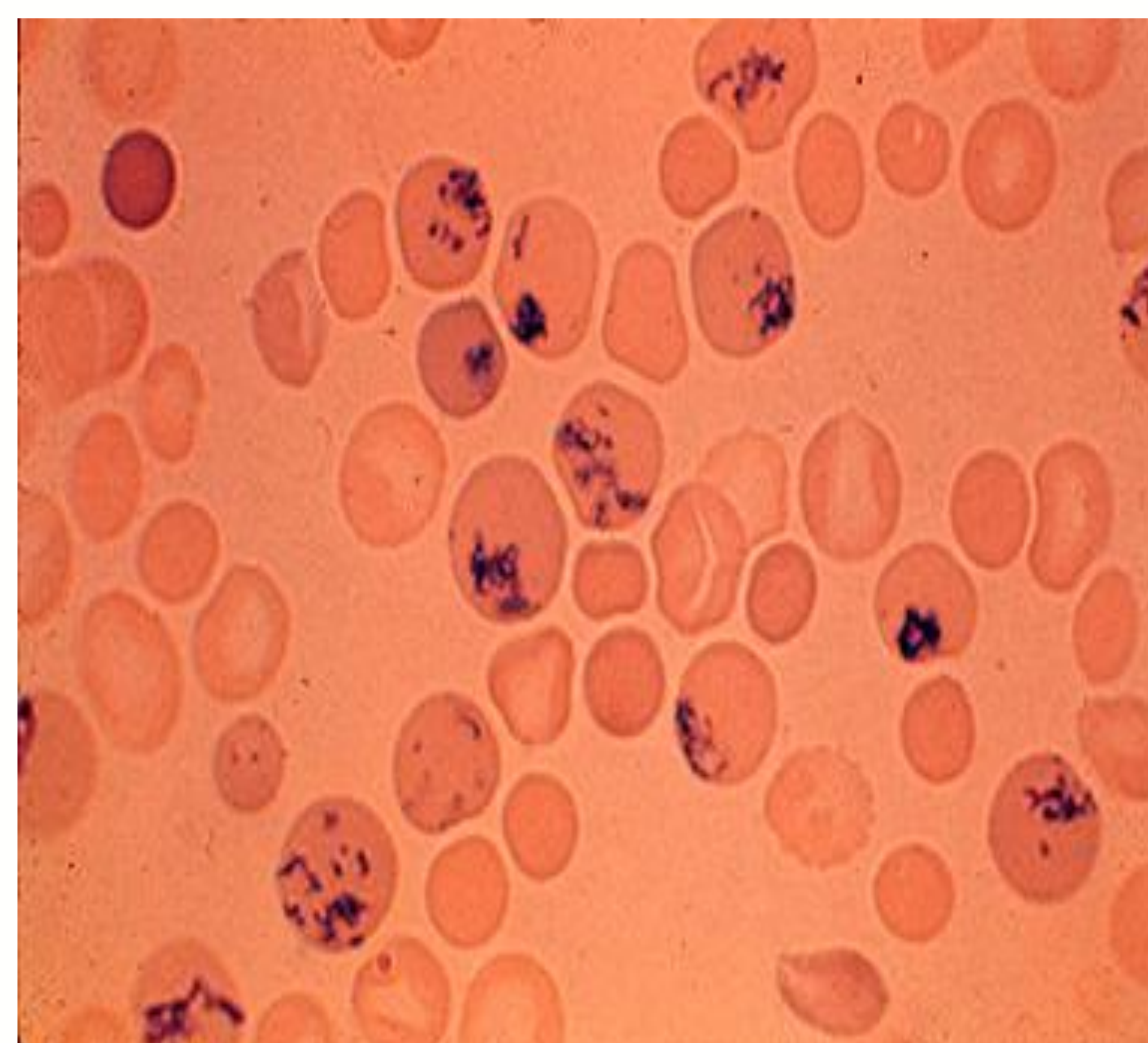
- Thrombotic thrombocytopenia purpura (TTP) is characterized by a pentad of fever, microangiopathic hemolytic anemia, thrombocytopenia, neurologic symptoms, and renal failure.
- To establish a diagnosis, only thrombocytopenia and microangiopathic hemolytic anemia are required.
- We present a rare case of a TTP without anemia but with clear cut microangiopathic hemolysis and thrombocytopenia.



Schistocytes*

Case Presentation

- A 32-year-old female with no significant past medical history except for polycystic ovary presented on a Friday afternoon with sore throat, headache, and low grade fever.
- The physical examination and the rest of her labs were within normal range except for thrombocytopenia with platelets of 46,000 per μL and mild macrocytosis (MCV -99) without anemia.
- The hemoglobin was normal at 12.4 gm/dl. The rest of the labs were drawn and she was asked to follow-up on Monday as immune thrombocytopenia was felt to be the most likely diagnosis.
- On Monday, the labs showed schistocytes on peripheral smear, reticulocytosis, and elevated LDH, consistent with TTP. By then, the patient had developed neurologic symptoms manifested by slurred speech.



Reticulocytes*

Discussion

- Since the patient was young, her bone marrow responded very well, and she developed adequate reticulocytosis that masked the anemia and resulted in macrocytosis.
- This case of TTP was unusual because it presented with macrocytosis without any anemia.
- She received plasmapheresis and achieved full recovery.

Conclusion

- Microangiopathic hemolysis and thrombocytopenia should lead to prompt consideration of TTP regardless of initial hemoglobin level, as anemia may not be present until TTP evolves.

References

- Cuttner J. Thrombotic thrombocytopenic purpura: a ten year experience. Blood 1980; 56:302-306.
Amorosi EL, Ultmann JE. Thrombocytopenic purpura: report of 16 cases and literature review. Medicine 1966; 45:139-159.

* Rosenthal DS. Evaluation of the peripheral blood smear. May 2011. <http://uptodate.com/>.