

Effect of Intravenous Phenobarbital on Left Ventricular Myocardial Contractility Determined by Echocardiography in Children

Arpan R. Doshi, M.D.^{1,2}, Monesha Gupta Malhotra, MBBS³,
Duraisamy Balaguru, M.D.⁴, Devendra Amre, M.D.⁵,
Christian Erikson, M.D.⁶

¹Children's Mercy Hospital & Clinics, Wichita, KS

²University of Kansas School of Medicine-Wichita

³Johns Hopkins All Children's Hospital, Johns Hopkins University, Saint Petersburg, FL

⁴Children's Memorial Hermann Hospital, McGovern Medical School, University of Texas Health Center, Houston, TX

⁵University of Montreal, Montreal, Canada

⁶Texas Children's Hospital, Baylor University, Houston, TX

Received Nov 7, 2018; Accepted for publication January 16, 2019; Published online May 15, 2019

ABSTRACT

Introduction. Animal studies and rare human studies have suggested a negative effect of barbiturates on cardiac function. Although intravenous (IV) phenobarbital is used routinely in children in the clinical setting, studies in children are lacking. We performed a study to evaluate effect of IV phenobarbital loading on myocardial systolic function of children.

Methods. In a prospective pilot study in children without congenital heart defects, the effect of IV phenobarbital was evaluated on the left ventricular systolic function measured by ejection fraction (EF) by Simpson's method via an echocardiogram. Any child less than 18 years of age who received IV loading dose of at least 20 mg/kg of phenobarbital given as an infusion over 20 - 30 minutes for various medical indications was eligible to take part in the study. Three measurements of EF by an echocardiogram were made: before loading dose, 30 minutes after completion of the loading dose, and prior to the first maintenance dose. Relevant clinical data were recorded, including vital signs, immediately prior to each echocardiogram. Change of function as measured by EF over time was analyzed using linear mixed modeling methods. For this study, significant change in blood pressure was defined as a drop of at least 20 mmHg in systolic blood pressure.

Results. Ten children (70% female, age range two days to 8.2 years) were enrolled. Three had hypotension with a drop of systolic blood pressure greater than 20 mmHg from baseline. On examining the trajectory of EF on each individual graphically, the left ventricular EF tended to fall immediately following phenobarbital therapy and return to baseline on re-evaluation. These trajectories were statistically significant for EF.

Conclusions. Phenobarbital had a direct and transient depressant effect on systolic function of the myocardium in one third of the cases. The depression in EF appeared to be transient with return to baseline

in less than 24 hours. We recommend close monitoring with anticipation of decreased function in children when using IV phenobarbital. *Kans J Med* 2019;12(2):40-44.

INTRODUCTION

Since the synthesis of phenobarbital in 1912, it remains the most widely prescribed antiepileptic drug worldwide despite the development of newer antiepileptic drugs.¹ Phenobarbital is used widely in pediatric population for seizures, especially neonatal seizures. It also is used for seizure prevention in traumatic brain injury,² neonatal opiate withdrawal,³ and resistant neonatal jaundice.^{4,5} Phenobarbital is derived from barbiturate and used as a hypnotic and sedative that can be administered via intravenous (IV), intramuscular (IM), and oral routes. Phenobarbital is absorbed almost completely via oral and IM route but duration of peak effect varies. It takes anywhere from one to six hours for peak effect of phenobarbital to occur after oral/IM administration. It takes only 30 minutes for peak effect to occur after IV phenobarbital administration. The clinical effect lasts for six to 10 hours after oral administration and four to 10 hours with IV administration of phenobarbital.⁶

Animal studies and rare human studies have suggested a negative effect of IV barbiturates on cardiac myocardial function.⁷⁻¹¹ Barbiturates have been associated with depression of the myocardial, respiratory, and nervous system. Hypotension after IV phenobarbital administration in adults has been described in pharmacology and epilepsy literature.¹

Overall, it is important to investigate the underlying mechanism of a well-known adverse reaction of a commonly-used medication in children. However, there are very few studies reported in the literature assessing myocardial depressant effect of IV barbiturate administration in humans, especially in children.^{12,13} A prospective pilot study was performed to evaluate the effect of IV phenobarbital on cardiac myocardial function in children by a transthoracic echocardiogram while monitoring the serum levels of phenobarbital.

METHODS

The study was approved by the institutional Committee for the Protection of Human Subjects (HSC-MS-12-0568) at the McGovern Medical School at the University of Texas Health Science Center and Children's Memorial Hermann Hospital, Texas Medical Center, Houston. All parents gave informed written consent for participation.

This prospective, single-center, pilot study was performed at the Pediatric Intensive Care Unit (PICU) at Children's Memorial Hermann Hospital between 2013 and 2014. Any child, age 0 - 19 years, who received IV loading dose of at least 20 mg/kg of phenobarbital in the PICU was eligible to take part in the study. Patient families were approached for the study only when the clinical condition required the use of IV phenobarbital and allowed enough time to enroll the child for the study and perform echocardiogram prior to administration of phenobarbital. Each child was used as their own control. Exclusion criteria included: (a) oral or intramuscular route used for phenobarbital loading dose and (b) any preexisting congenital heart defect.

An IV loading dose of phenobarbital, at least 20 mg/kg, was given as IV infusion over 20 - 30 minutes for various medical indications as determined by the intensivist. An echocardiogram per protocol was performed before and after the loading dose. For the study, the vital signs were recorded immediately prior to each echocardiogram. According to the protocol, multiple cycled blood pressures were obtained every 15 minutes for one hour, every 30 minutes for one hour, then every 60 minutes via oscillometric technique using appropriate cuffs in all critical patients in the PICU. The clinical data were extracted from the medical records once the child was enrolled for the study. The echocardiograms were performed by a senior pediatric cardiology fellow in a majority of the cases. The echocardiogram parameters were measured before and after the administration of IV phenobarbital and the measurements were evaluated and reported by a single cardiologist in an unblinded fashion. Since the children could be hypertensive or hypotensive at various time points, a significant change in blood pressure was defined as a drop of at least 20 mmHg in systolic blood pressure (SBP). Phenobarbital serum levels also were recorded after the loading dose to establish level related effect and the therapeutic levels were considered between 15 - 40 mcg/ml.

Transthoracic echocardiograms were performed prospectively on each patient. All echocardiograms were performed by a qualified pediatric cardiac sonographer or a senior pediatric cardiology fellow per protocol. The first echocardiogram was performed immediately prior to administration of phenobarbital loading dose. A second echocardiogram was performed 30 minutes after completion of the loading dose of phenobarbital and a third echocardiogram was performed prior to the first maintenance dose of phenobarbital usually starting 12 - 24 hours after loading dose.

On the first echocardiogram, screening was performed to rule out any major structural heart defect using a standard pediatric echocardiography protocol,^{14,15} including two-dimensional (2D), M-Mode, and Doppler measurements. All were interpreted by a board certified pediatric cardiologist in a blinded manner. All measurements were performed using commercially available single software (AGFA Heartlab Cardiovascular; AGFA Healthcare, Greenville, SC, USA). The left ventricular (LV) dimensions were measured from the M-mode echocardiogram obtained at the level of papillary muscle in parasternal short- and long-axis views. The left ventricular end-diastolic dimension (LVEDD) was measured at the end of diastole (beginning of QRS-complex). The left ventricular end-systolic dimension (LVESD) was measured at the closest point of apposition between the septum and inferolateral wall. The shortening fraction (SFM) and ejection fraction (EFM) using the M-Mode data were calculated as markers to quantify systolic cardiac function.^{14,15} The ejection fraction (EFS) using the biplane Simpson's formula from 2D evaluations of the left ventricular volumes were calculated in the standard manner.^{14,15}

To examine the pattern/trajectory of the change in the left ventricular systolic function parameters (SFM, EFM, EFS) over time, graphical and statistical methods were used. The changes over the three time periods for each patient were assessed. Based on the visualized trajectories, linear mixed models were fit to the data. These

models enabled the modelling of both fixed and random effects and took into account the correlation between the repeated measures. A simple univariate model was fit with the left ventricular systolic function parameters as the outcome and time as the covariate. A random effect for each individual was fit. First, a model assuming a linear slope was fit. Subsequently, a model assuming a quadratic curve was fit. The model that best fit the data was assessed by log-likelihood ratio statistics. A p-value of 0.05 was set to indicate statistical significance.

RESULTS

During the study period, 10 participants were recruited for this pilot study, where each child served as their own control (Table 1). Mean age of patients in months was 21.8 (\pm 38.5), age range was from two days to 8.2 years, 70% were females, five (50%) were African Americans, two (20%) were Caucasians, and three (30%) were Hispanics. During the screening echocardiogram, no patients had significant congenital heart disease and none had a history of a pre-existing cardiovascular disease.

The medical indications for use of IV phenobarbital were seizure prevention in traumatic brain injury (n = 5) and seizures (n = 5). Three children had both head trauma and seizures. One child was diagnosed with meningitis and none of the children were diagnosed with sepsis during the study. Figure 1 demonstrates the change in SBP, heart rates, and EF measures in all 10 children administered IV phenobarbital over time. Eight children were receiving respiratory support using a ventilator during the study duration prior to the first dose of phenobarbital. One child was on high flow nasal cannula and another was on room air with saturations via pulse oximetry above 95%. None of the children were on any vasoactive or inotropic medications prior to the first echocardiogram except one child who was on IV dopamine infusion at the same dose during the first and second echocardiograms and a lower dose during the third echocardiogram. Of the 10 children, seven had a serum phenobarbital level obtained after the infusion and were in the therapeutic range or higher (Table 1). No child developed significant bradycardia or a rash during the study.

Table I. Clinical characteristics of the study population.

	Age (months)	Gender	Weight (kg)	BSA	Race	Indication	Phenobarbital Level (mcg/ml)
1	90.25	F	36.8	1.09	Hispanic	Seizure	16.6
2	3.22	F	5.57	0.29	African American	Seizure	28.7
3	2.92	M	5.8	0.29	Caucasian	Seizure, cardiac arrest	23.1
4	0.06	F	6.52	0.26	Caucasian	Seizure, head trauma	
5	9.72	F	8.9	0.38	Hispanic	Head trauma	
6	1.11	F	3.8	0.21	African American	Meningitis, seizure	42.1
7	7.98	M	10.3	0.42	African American	Seizure, head trauma	
8	1.37	F	4.7	0.25	Hispanic	Seizure, head trauma	57.8
9	2.96	M	3.8	0.23	African American	Head trauma, cardiac arrest	17.9
10	98.8	F	17.2	0.71	African American	Seizure	42.6

Kg, kilogram; mcg/ml, micrograms per milliliters

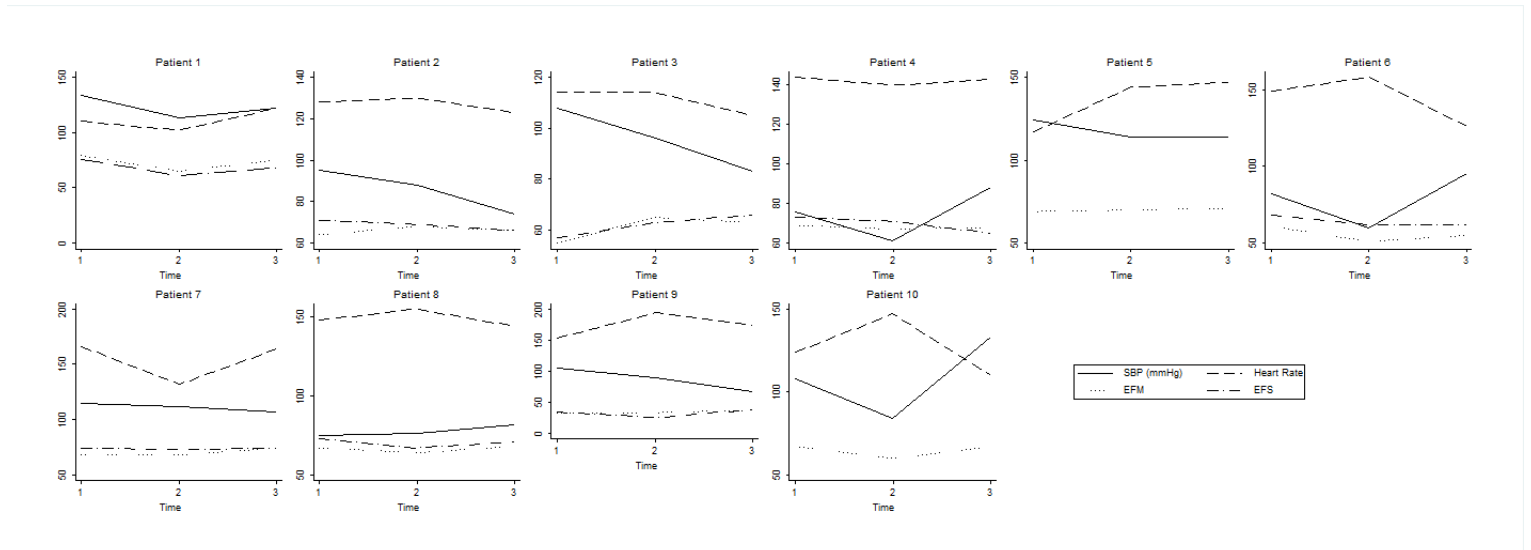


Figure 1. Trajectory of the change in the systolic blood pressure in mmHg (SBP), heart rate in beats per minute (HR), and left ventricular ejection fraction percent by M-mode (EFM) and by Simpson's method (EFS) over time in each child.

Table 2 demonstrates the evolution of echocardiographic measures in children administered phenobarbital. On examining the trajectory of each individual (Figure 1), the left ventricular systolic function parameters tended to fall in the first 12 hours following phenobarbital therapy. Subsequently, the levels of parameters tended to rise, in most circumstances reaching the baseline levels after 24 hours. As seen in Figure 1, the heart rate and blood pressure response were variable for each child and did not fit any pattern. Given these trajectories, we compared the fit of both the linear and quadratic models. As shown in Figure 1, the quadratic model appeared to fit the data well. Analysis using the mixed models technique (Table 2) showed that for all the three parameters, the levels appeared to fall just subsequent to therapy (negative coefficient for time) and rise thereafter (positive coefficient for time square). These trajectories were statistically significant for EFS.

Table 2. Evolution of left ventricular systolic function in patients administered phenobarbital.

Echocardiogram measure	β coefficient [†]	95% CI	p-value
SFM			
Time	-6.5	-14.2 - 1.24	0.10
Time x Time	1.8	-0.12 - 3.71	0.065
EFM			
Time	-9.9	-20.7 - 0.83	0.07
Time x Time	2.65	-0.01 - 5.32	0.051
EFS			
Time	-14.7	-28.4 - -1.03	0.03*
Time x Time	3.4	0.03 - 6.82	0.048*

[†]Findings of mixed model linear regression analysis.

*p-value < 0.05.

SFM, shortening fraction by M-mode; EFM, ejection fraction by M-mode; EFS, ejection fraction by Simpson's biplane.

There was significant drop in SBP in three of the 10 children along with a significant drop in systolic left ventricular function between first and second echocardiograms that were done before and after IV phenobarbital of 20 mg/kg respectively. None of these three children were on any vasoactive or inotropic medications between first and second echocardiograms. The first child with seizures, on a ventilator, had 21 mmHg drop in SBP with a 14-point decrease in EFM after phenobarbital loading dose with a serum phenobarbital level of 16.6 mcg/ml. The second child with seizures, on a ventilator, had a 22 mmHg drop in SBP with a 10-point decrease in EFM after phenobarbital loading dose with a serum phenobarbital level of 42.1 mcg/ml. The third child with seizures, on room air, had a 24 mmHg drop in SBP after phenobarbital loading dose with a 7-point decrease in EFM with a serum phenobarbital level of 42.6 mcg/ml. The left ventricular systolic function improved to near that of the baseline for all three children at the time of third echocardiogram. Overall, there was no significant correlation between the serum phenobarbital levels and hypotension.

DISCUSSION

Although IV phenobarbital is used routinely in children in the clinical setting, hemodynamic studies with its use in children are lacking. Our pilot study analyzed clinical and left ventricular myocardial contractility data with ejection fraction (EF) measured by an echocardiogram via Simpson's method obtained from children before and after IV phenobarbital with a loading dose of at least 20 mg/kg. The findings suggested a transient direct myocardial depressant effect of phenobarbital that occurs 30 minutes after completion of the loading dose but recovers prior to beginning of the maintenance dose.

Previous animal studies suggested negative effect on left ventricular function with use of barbiturates.⁷⁻⁹ These animal studies have shown direct depression of myocardial function with barbiturates as noted by decrease in EF⁸ and cardiac function⁹ with pentobarbital. Manders et al.⁷ studied the effect of pentobarbital IV in 30 conscious dogs instrumented for measurement of hemodynamics, including cardiac output and regional blood flow distribution, left ventricular diameter, left ventricular pressure, and dP/dt and dD/DT (velocity of myocardial fiber shortening). Pentobarbital affected systemic and regional hemodynamics only slightly, but depressed the myocardium markedly. They concluded that induced tachycardia was not due to only vagolytic effect as previously thought, but is mediated predominantly through the arterial baroreceptor reflex.

Two previous studies in children have reported no significant change in EF with rectal barbiturate, methohexital. A study in children using rectal 10% methohexital at 30 mg/kg found that the left ventricular EF, blood pressure, and cardiac index remained in the normal range, but there was a significant increase in heart rate and decrease in stroke volumes.¹² Another study in children using rectal 2% methohexital 25 mg/kg found a significant increase in heart rate, but unchanged blood pressure, cardiac index, stroke volume, and left ventricular EF.¹³ Both studies concluded that rectal methohexital could be used safely in healthy pediatric patients with minimal hemodynamic effect.

A known side effect of phenobarbital in adults is hypotension or a decrease in systolic blood pressures which was seen in 30% of our children. Since a previous study of IV phenobarbital use is not available in children, the findings from our study suggested that a clinician treating children should be prepared for a transient hypotension with IV phenobarbital in one third of the cases and also to use the medication with caution in those with preexisting depressed left ventricular function. In our study, three children who received an IV bolus of phenobarbital for indication of seizures showed evidence of a significant drop in systolic blood by 20 mmHg or greater after IV phenobarbital load. The same three patients also showed significant myocardial depression with a decrease in the left ventricular EF by an echocardiogram after the IV phenobarbital load that returned to baseline prior to first maintenance dose of phenobarbital. There was no evidence that these measured changes were dependent on the

phenobarbital dose or serum level, since all children had similar loading doses and their serum levels did not correlate with their EF. There could have been a decrease in blood pressure and myocardial function in these children over time especially if there were ongoing seizures or other systemic insults such as trauma, hypoxia, and cardiopulmonary arrest. However, since our timed echocardiogram studies before and after loading of phenobarbital were obtained prospectively, this was less likely. Moreover, previous adult human studies were in agreement with our findings. An adult study using IV infusion of phenobarbital for refractory seizures demonstrated hypotension requiring fluid resuscitation and vasopressors was seen in 32% of the cases.¹⁶ Another study in adults, a randomized trial using IV Thiopentone 5 mg/kg in patients with coronary artery disease and left ventricular dysfunction showed a similar hemodynamic response in comparison to three other anesthetic agents that were evaluated, with a 30% - 40% decrease in cardiac index.¹⁷

Although this pilot study provides useful information for clinicians, a small sample size in this prospective single center pilot study was the most significant limitation. A larger multicenter study is recommended to confirm the findings and evaluate other clinical confounders that were not evaluated in this study. Due to the prospective and time-based nature of the study, other sophisticated echocardiographic parameters of systolic and diastolic function were not obtained, such as myocardial performance index, strain imaging, 3D imaging, and tissue Doppler imaging to evaluate myocardium in more detail. Hence, further studies with a larger sample size looking at extensive systolic and diastolic function and physiology of peripheral vasculature are warranted.

CONCLUSIONS

This pilot study in children showed that IV phenobarbital had a direct depressant effect on contractility of the left ventricular myocardium. The decrease in left ventricular EF appeared to be transient with return to baseline in less than 24 hours. There was an accompanying transient decrease in systolic blood pressure in 30% of the children. We recommend close monitoring with anticipation of decreased function in children when using IV phenobarbital.

ACKNOWLEDGEMENT

We thank the patients and their family members that allowed us to perform this study. Authors acknowledge the support with a waiver of the charges for the echocardiogram performed as part of this study from Children's Memorial Hermann Hospital and Memorial Hermann Texas Medical Center.

REFERENCES

- 1 Kwan P, Brodie MJ. Phenobarbital for the treatment of epilepsy in the 21st century: A critical review. *Epilepsia* 2004; 45(9):1141-1149. PMID: 15329080.
- 2 Kochanek PM, Carney N, Adelson PD, et al. Guidelines for the acute medical management of severe traumatic brain injury in infants, children, and adolescents--second edition. *Pediatr Crit Care Med* 2012; 13(Suppl 1):S1-S82. PMID: 22217782.
- 3 Osborn DA, Jeffery HE, Cole MJ. Opiate treatment for opiate withdrawal in newborn infants. *Cochrane Database Syst Rev* 2010; (10):CD002059. PMID: 20927730.
- 4 Chawla D, Parmar V. Phenobarbitone for prevention and treatment of unconjugated hyperbilirubinemia in preterm neonates: A systematic review and meta-analysis. *Indian Pediatr* 2010; 47(5):401-407. PMID: 19736369.
- 5 Hamidi M, Zamanzad B, Mesripour A. Comparing the effect of clofibrate and phenobarbital on the newborns with hyperbilirubinemia. *EXCLI J* 2013; 12:75-78. PMID: 26417217.
- 6 Heimann G, Gladtko E. Pharmacokinetics of phenobarbital in childhood. *Eur J Clin Pharmacol* 1977; 12(4):305-310. PMID: 590316.
- 7 Manders WT, Vatner SF. Effects of sodium pentobarbital anesthesia on left ventricular function and distribution of cardiac output in dogs, with particular reference to the mechanism for tachycardia. *Circ Res* 1976; 39(4):512-517. PMID: 963835.
- 8 Popovic VP, Kent KM. 120-day study of cardiac output in unanesthetized rats. *Am J Physiol* 1964; 207:767-770. PMID: 14220059.
- 9 Stein AB, Tiwari S, Thomas P, et al. Effects of anesthesia on echocardiographic assessment of left ventricular structure and function in rats. *Basic Res Cardiol* 2007; 102(1):28-41. PMID: 17006633.
- 10 Howard RJ, Stopps TP, Moe GW, Armstrong PW. A new method for hemodynamic and echocardiographic assessment of conscious dogs: Comparison with thiopental-morphine anaesthesia. *Clin Invest Med* 1990; 13(1):6-10. PMID: 2311313.
- 11 Unruh HW, Wang R, Bose D, Mink SN. Does pentobarbital anesthesia depress left ventricular contractility in dogs? *Am J Physiol* 1991; 261(3 Pt 2):H700-706. PMID: 1887918.
- 12 Audenaert SM, Lock RL, Johnson GL, Pedigo NW Jr. Cardiovascular effects of rectal methohexital in children. *J Clin Anesth* 1992; 4(2):116-119. PMID: 1562334.
- 13 Forbes RB, Murray DJ, Dull DL, Mahoney LT. Haemodynamic effects of rectal methohexitalone for induction of anaesthesia in children. *Can J Anaesth* 1989; 36(5):526-529. PMID: 2791176.
- 14 Lai WW, Geva T, Shirali GS, et al. Guidelines and standards for performance of a pediatric echocardiogram: A report from the Task Force of the Pediatric Council of the American Society of Echocardiography. *J Am Soc Echocardiogr* 2006; 19(12):1413-1430. PMID: 17138024.
- 15 Lopez L, Colan SD, Frommelt PC, et al. Recommendations for quantification methods during the performance of a pediatric echocardiogram: A report from the Pediatric Measurements Writing Group of the American Society of Echocardiography Pediatric and Congenital Heart Disease Council. *J Am Soc Echocardiogr* 2010; 23(5):465-495. PMID: 20451803.
- 16 Pugin D, Foreman B, De Marchis GM, et al. Is pentobarbital safe and efficacious in the treatment of super-refractory status epilepticus: A cohort study. *Crit Care* 2014; 18(3):R103. PMID: 24886712.
- 17 Singh R, Choudhury M, Kapoor PM, Kiran U. A randomized trial of anesthetic induction agents in patients with coronary artery disease and left ventricular dysfunction. *Ann Card Anaesth* 2010; 13(3):217-223. PMID: 20826962.

Keywords: phenobarbital, myocardial contractility, echocardiography, ventricular function, child