

CASE REPORT

Vena Cava Filter Complications: Aortic Pseudoaneurysm Presenting as a Gastrointestinal Bleed

Patrick G. McEnulty, M.D.¹, William J. Salyers, Jr., M.D.¹,
Akash Joshi, M.D.²

University of Kansas School of Medicine-Wichita,

¹Department of Internal Medicine

²Department of Diagnostic Radiology

Received June 29, 2018; Accepted for publication February 5, 2019; Published online May 15, 2019

INTRODUCTION

Vena cava filters (VCFs) have been employed at a rapidly growing pace over the last two decades.^{1,2} In fact, VCFs are placed in patients in the United States at an estimated rate of 25 times that in Europe.³ Likewise, the number of reported complications from VCFs also has increased significantly.^{1,4} The growing collection of literature on VCFs has led to an increased awareness of potential adverse outcomes after filter insertion, and emphasis on appropriate prevention and treatment of these complications. We present an unusual case of abdominal aortic pseudoaneurysm resulting from VCF perforation in a young patient who presented with hematemesis.

CASE REPORT

A 24-year-old male with a history of paraplegia presented as a transfer from an outside facility after two episodes of hematemesis and acute blood loss anemia. His hemoglobin level dropped from 11.7 to 8.0 g/dL between the time of transfer and admission. A VCF had been inserted over three years prior; documentation of indication for the VCF was unavailable. The patient underwent esophagogastroduodenoscopy which revealed a pulsating deformity at the third portion of the duodenum associated with two superficial erosions that were not actively bleeding. No endoscopic interventions were performed. Computed tomography angiography (CTA) of the abdomen was subsequently performed showing an extraluminal VCF strut penetrating into the abdominal aorta (Figures 1 and 2). This was associated with a pseudoaneurysm projecting into the duodenal wall at the level of the inferior mesenteric artery (Figure 3).

Vascular surgery recommended that the patient be transferred to a higher level of care for aortic and inferior vena cava reconstruction. Prior to transferring, the patient became acutely hypotensive, diaphoretic, and exhibited a decreased level of consciousness. He was taken to the operating room for emergent abdominal endovascular aortic repair (EVAR), after which he remained hemodynamically stable. He was transferred to another facility for excision of the pseudoaneurysm and graft placement.

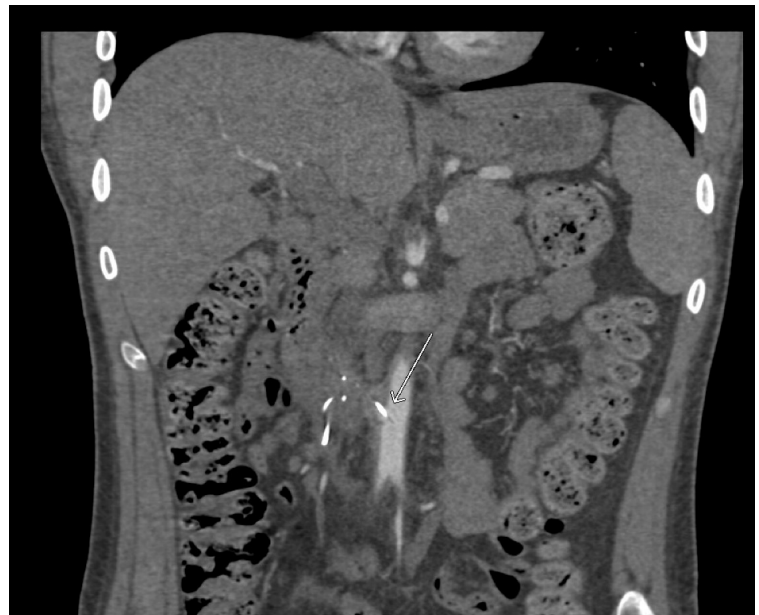

Figure 1. CT angiogram, coronal view, showing a strut penetrating the wall of the aorta.

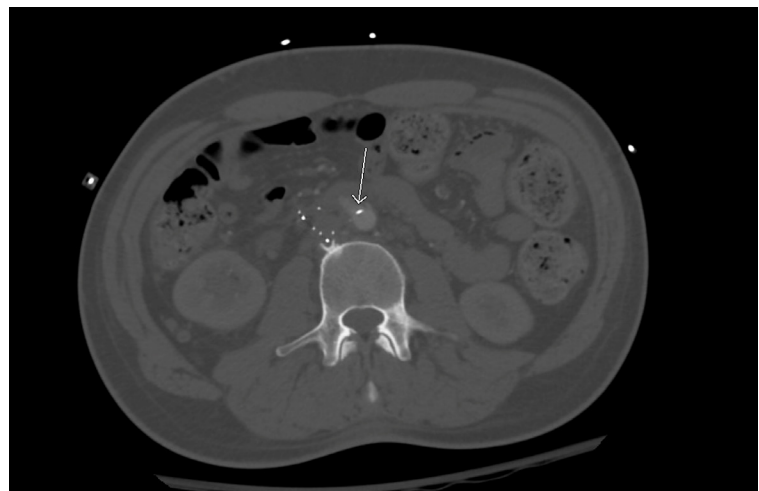


Figure 2. CT angiogram, axial view, showing a strut penetrating the wall of the aorta at the level of the third portion of the duodenum.

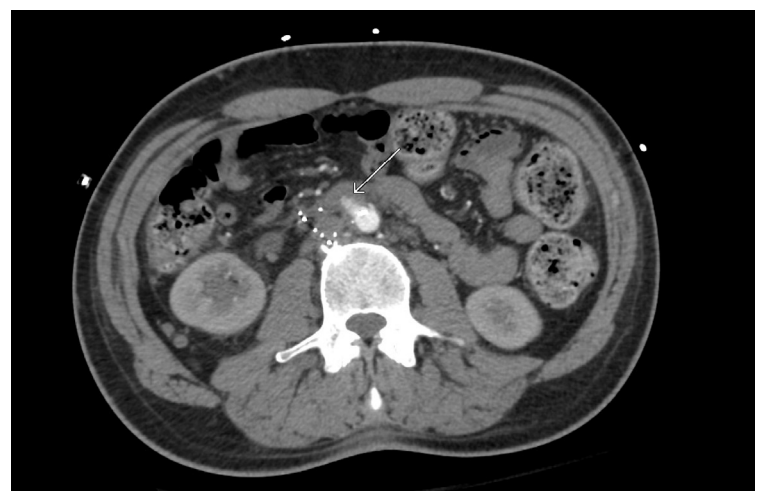

Figure 3. CT angiogram, axial view, showing an aortic pseudoaneurysm projecting into the wall of the third portion of the duodenum.

DISCUSSION

In general, VCFs are thought to be reasonably safe interventions when appropriately indicated, with total major complication rates less than 0.5%.⁵ However, VCFs may occasionally result in significant and sometimes life-threatening complications.⁶ Perforation of VCF struts into gastrointestinal (GI) organs, vertebra, ureter, mesenteric vessels, and aorta have been reported previously.^{1,7-12} Recognition of vena cava filter malfunction can be difficult to detect, and depending on the complication, can require highly specialized, multidisciplinary interventions.^{6,13}

Indications for VCF insertion are either therapeutic or prophylactic.^{12,14} For example, VCFs were developed originally for therapeutic intervention in the case of pulmonary embolism (PE) recurrence. Prophylactically, VCFs can be used when the risk for PE is thought to be very high, such as in the case of paralysis when pharmacologic anticoagulation is contraindicated.¹⁴⁻¹⁶

Perforation of a VCF strut is defined as penetration greater than 3 mm beyond the vena cava wall and is not a particularly rare complication.¹⁰ Perforation of the cava wall with or without involvement of adjacent structures accounts for 9% - 25% of all VCF complications.^{4,10,17,18} In cases where a strut has perforated the vena cava wall, about 5% lead to significant complications.^{12,17} While multiple factors seem to be associated with higher perforation rates in various kind of VCFs longer indwelling times increase the chance of strut penetration regardless of what type of filter is used.¹⁹

While there are evidenced-based reasons to use VCFs in the appropriate context, the potential serious consequences of complications like strut perforation necessitate careful consideration of the benefits and risks, as well as alternatives, prior to insertion.^{12,14} Likewise, when VCFs are utilized, regular surveillance and use of retrievable filters can be effective in preventing deleterious complications such as aortic aneurysms, though specific surveillance methods and time intervals are not agreed upon.¹³

Whereas strut perforation is relatively common, the incidence of pseudoaneurysms arising as a consequence of VCF perforation is exceptionally rare.²⁰ A comprehensive search of the literature reveals very few cases reporting pseudoaneurysm formation resulting from VCF strut perforation.²¹⁻²³ This case demonstrated the context in which pseudoaneurysm formation may occur, and the symptoms with which it may present. In a patient with a history of VCF placement who presents with a GI bleed, it is important to recognize this potentially lethal complication when formulating a differential in order to ensure prompt management.

REFERENCES

- 1 Jehangir A, Rettew A, Shaikh B, et al. IVC filter perforation through the duodenum found after years of abdominal pain. *Am J Case Rep* 2015; 16:292-295. PMID: 25979859.
- 2 Alkhouli M, Bashir R. Inferior vena cava filters in the United States: Less is more. *Int J Cardiol* 2014; 177(3):742-743. PMID: 25131922.
- 3 Wang SL, Lloyd AJ. Clinical review: Inferior vena cava filters in the age of patient-centered outcomes. *Ann Med* 2013; 45(7):474-481. PMID: 24099038.
- 4 Weinberg I, Kaufman J, Jaff MR. Inferior vena cava filters. *JACC Cardiovasc Interv* 2013; 6(6):539-547. PMID: 23787230.
- 5 Montgomery JP, Kaufman JA. A critical review of available retrievable inferior vena cava filters and future directions. *Semin Intervent Radiol* 2016; 33(2):79-87. PMID: 27247475.
- 6 Veroux M, Tallarita T, Pennisi M, Veroux P. Late complication from a retrievable inferior vena cava filter with associated caval, aortic, and duodenal perforation: A case report. *J Vasc Surg* 2008; 48(1):223-225. PMID: 18589238.
- 7 Bae MJ, Chung SW, Lee CW, Kim S, Song S. Duodenal perforation caused by an inferior vena cava filter. *Korean J Thorac Cardiovasc Surg* 2012; 45(1):69-71. PMID: 22363914.
- 8 Botsios S, Erhart R, Walterbusch G. [Acute gastrointestinal bleeding caused by perforation of a Greenfield caval filter into the duodenum]. *Dtsch Med Wochenschr* 2006; 131(48):2715-2717. PMID: 17123237.
- 9 Joels CS, Sing RF, Heniford BT. Complications of inferior vena cava filters. *Am Surg* 2003; 69(8):654-659. PMID: 12953821.
- 10 Malgor RD, Labropoulos N. A systematic review of symptomatic duodenal perforation by inferior vena cava filters. *J Vasc Surg* 2012; 55(3):856-861. e3. PMID: 22209606.
- 11 Park JR, Oza VM, Krishna SG. Asymptomatic duodenal perforation from an inferior vena cava filter. *ACG Case Rep J* 2014; 1(3):143-144. PMID: 26157855.
- 12 Streiff MB. Vena caval filters: A comprehensive review. *Blood* 2000; 95(12):3669-3677. PMID: 10845895.
- 13 Vyas A, Malas A, Marshall G, Harb A, Stawick L, Svinarich D. Duodenal perforation by an IVC filter: A case and discussion expanding on the 2010 guidelines for filter retrieval. *Cardiovasc Intervent Radiol* 2014; 37(3):847-849. PMID: 24196268.
- 14 Rutherford RB. Prophylactic indications for vena cava filters: Critical appraisal. *Semin Vasc Surg* 2005; 18(3):158-165. PMID: 16168892.
- 15 Datta I, Ball CG, Rudmik L, Hameed SM, Kortbeek JB. Complications related to deep venous thrombosis prophylaxis in trauma: A systematic review of the literature. *J Trauma Manag Outcomes* 2010; 4:1. PMID: 20205800.
- 16 Chung J, Owen RJ. Using inferior vena cava filters to prevent pulmonary embolism. *Can Fam Physician* 2008; 54(1):49-55. PMID: 18208955.
- 17 Jia Z, Wu A, Tam M, Spain J, McKinney JM, Wang W. Caval penetration by inferior vena cava filters: A systematic literature review of clinical significance and management. *Circulation* 2015; 132(10):944-952. PMID: 26169756.
- 18 Kinney TB. Update on inferior vena cava filters. *J Vasc Interv Radiol* 2003; 14(4):425-440. PMID: 12682199.
- 19 Durack JC, Westphalen AC, Kekulawela S, et al. Perforation of the IVC: Rule rather than exception after longer indwelling times for the Günther Tulip and Celect retrievable filters. *Cardiovasc Intervent Radiol* 2012; 35(2):299-308. PMID: 21448771.
- 20 Grewal S, Chamrath MR, Kalva SP. Complications of inferior vena cava filters. *Cardiovasc Diagn Ther* 2016; 6(6):632-641. PMID: 28123983.
- 21 Campbell JJ, Calcagno D. Aortic pseudoaneurysm from aortic penetration with a bird's nest vena cava filter. *J Vasc Surg* 2003; 38(3):596-599. PMID: 12947283.
- 22 Medina CR, Indes J, Smith C. Endovascular treatment of an abdominal aortic pseudoaneurysm as a late complication of inferior vena cava filter placement. *J Vasc Surg* 2006; 43(6):1278-1282. PMID: 16765254.
- 23 Putterman D, Niman D, Cohen G. Aortic pseudoaneurysm after penetration by a Simon nitinol inferior vena cava filter. *J Vasc Interv Radiol* 2005; 16(4):535-538. PMID: 15802454.

Keywords: vena cava filter, gastrointestinal hemorrhage, pseudoaneurysm