

Clot in Transit and Pulmonary Artery Percutaneous Mechanical Thrombectomy

Scott E. Janus, M.D.¹, Jamal Hajjari, M.D.¹, Tarek Chami, M.D.¹,
Mohamad Karnib, M.D.¹, Mohammed Najeeb Osman, M.D.^{1,2}

¹University Hospital Cleveland Medical Center, Cleveland, OH
Harrington Heart and Vascular Institute

²Case Western Reserve University, Cleveland, OH
Department of Medicine

Received June 8, 2021; Accepted for publication July 20, 2021; Published online Nov 5, 2021
<https://doi.org/10.17161/kjm.voll4.15601>

INTRODUCTION

Despite an abundance of literature supporting percutaneous mechanical thrombectomy of pulmonary embolism (PE), only a limited number of case reports in the literature attest to the utility of percutaneous mechanical thrombectomy for clot in transit.^{1,2} With a recent U.S. Food and Drug Administration (FDA) approval for the FlowTrieve[®] system for percutaneous mechanical thrombectomy for clot in transit,³ we present a dramatic case with recent trimalleolar fracture, having undergone open reduction and internal fixation, post-operative course being complicated by extensive deep vein thrombosis with resultant pulmonary embolism and clot in transit which was extracted successfully using the percutaneous mechanical thrombectomy FlowTrieve[®] system.

CASE REPORT

A 59-year-old male with past medical history of atrial fibrillation on rivaroxaban, hypertension, morbid obesity, and heart failure with preserved ejection fraction presented with shortness of breath after being discharged from a same day surgical facility for a malleolar fracture repair. He had a fall and suffered a trimalleolar ankle fracture. After holding his rivaroxaban for three days prior to surgery, he underwent internal fixation of the left trimalleolar ankle fracture and was discharged the same day.

Upon trying to exit his car at a fast-food restaurant, the patient had severe shortness of breath and was brought to the emergency room. In the emergency room, he was tachycardic with a heart rate of 137 beats per minute, blood pressure of 95/61 mmHg, and respiratory rate of 18 per minute with an oxygen saturation 96% on 4 liters by nasal cannula. His exam was significant for clear lungs bilaterally, but with increased effort for breathing. Heart examination was irregular without any significant murmurs. He had 1+ edema bilaterally. The differential diagnosis included pulmonary embolism, fat embolism, acute coronary syndrome, and aortic dissection.

Electrocardiogram revealed atrial fibrillation with rapid ventricular rate and low voltage (Figure 1). His blood work was significant for a hemoglobin 13.9 g/dL, white blood cell count of 8.2 x 10⁹/L, platelet count of 137 x 10⁹/L, and creatinine of 1.19 mg/dL. Troponin I returned at 0.04 ng/mL along with an elevated whole blood lactate 5.1 mmol/L. Due to concern for pulmonary embolism, he underwent computed tomography angiogram of the chest which demonstrated a large throm-

bus burden in the right and left pulmonary arteries with extension into the segmental branches of the left upper, left lower, right lower, and right middle lobes (Figure 2, Video 1) along with an impressive clot in transit in the right atrium (Figure 3). The clot in transit was passing in/out of the tricuspid valve and not attached to any intracardiac structure. The pulmonary embolism response (PERT) team was activated. Given the recent surgery and extensive clot in transit, systemic thrombolysis was avoided despite borderline hemodynamics. He was brought to the catheterization lab where he underwent echocardiography-guided (Figure 4, Video 2) extirpation of the clot in transit (Video 3) and from bilateral pulmonary arteries (Figure 5). [Videos are only available on the website: journals.ku.edu/kjm].

A post procedure echocardiogram (Figure 6, Video 4) demonstrated resolution of the clot in transit in the right atrium, along with dramatic improvement in hemodynamics with heart rate of 79 beats per minute, respiratory rate of 15 per minute, saturating 98% without requiring supplemental oxygen, and blood pressure of 122/99 mmHg. He underwent bilateral lower extremity duplex which showed acute occlusive deep vein thrombosis in the right popliteal and posterior tibial veins. He was started on warfarin with heparin bridging following the procedure. He was discharged on day five, and a plan for a vascular medicine follow-up for hypercoagulable workup as an outpatient.

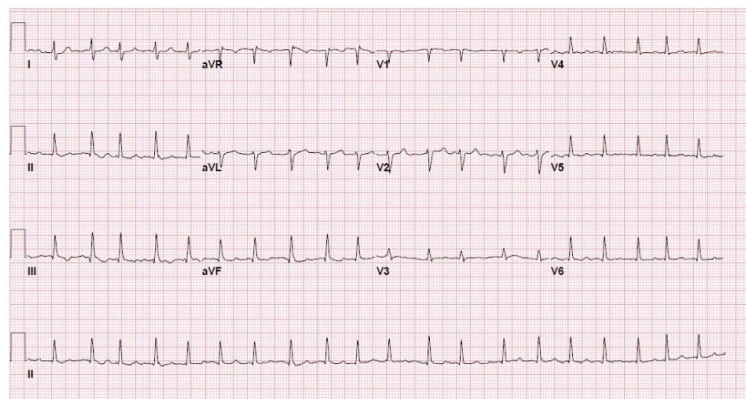


Figure 1. Electrocardiogram demonstrates atrial fibrillation with rapid ventricular rate with ST, T3 inversion.

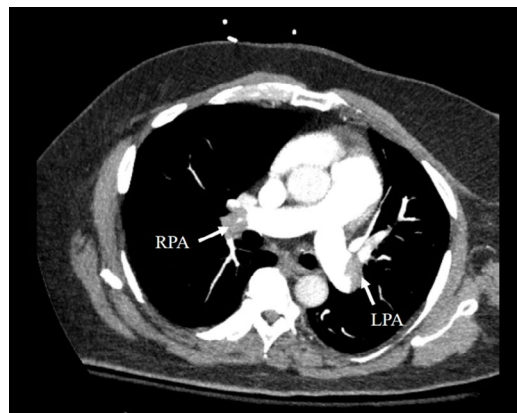


Figure 2. Computed tomography angiogram of chest (pulmonary embolism protocol) demonstrates large bilateral pulmonary artery embolisms (RPA right pulmonary artery; LPA left pulmonary artery).

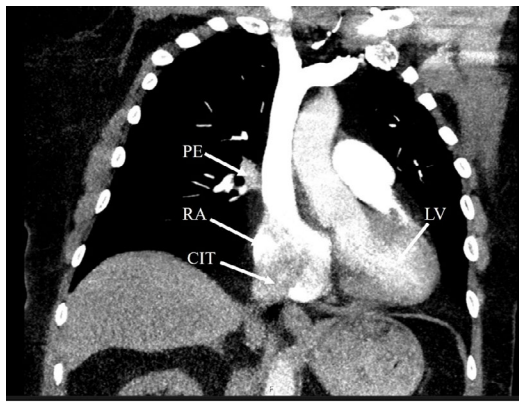


Figure 3. Computed tomography angiogram of chest (pulmonary embolism protocol) demonstrates large clot in transit (CIT), PE (pulmonary embolism), LV (left ventricle), RA (Right atrium).

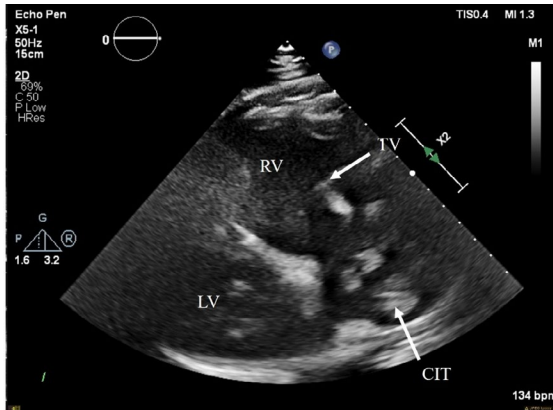


Figure 4. Echocardiogram, right ventricle tilt view demonstrates clot in transit (CIT), TV (tricuspid valve), RV (right ventricle), LV (left ventricle).

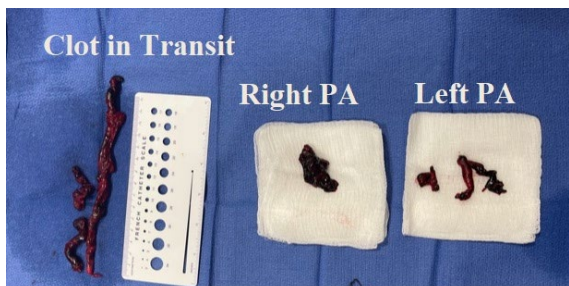


Figure 5. Clot in Transit, Right PA (Pulmonary artery), and Left PA (Pulmonary artery).

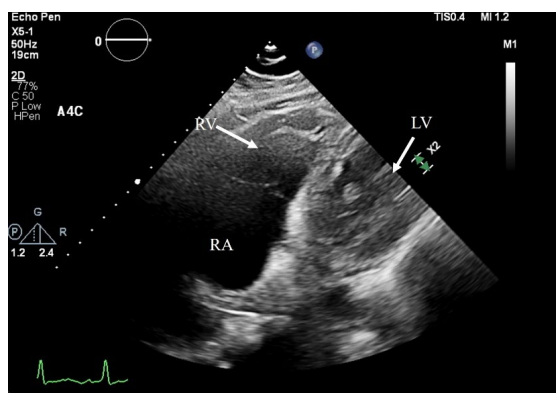


Figure 6. Echocardiogram post procedure demonstrates resolution of the clot in transit, TV (tricuspid valve), RV (right ventricle), and LV (left ventricle).

DISCUSSION

This case demonstrated safe application of percutaneous mechanical thrombectomy in a patient with a clot in transit in the right atrium. While percutaneous mechanical thrombectomy has revolutionized the treatment of pulmonary embolism,⁴ relatively little data exist on the

safety and efficacy of the utility of percutaneous therapies for clot in transit (CIT).¹ Despite obtaining FDA approval,³ this application of the FlowTrieve[®] system remains under-described and is vitally important to be recognized.

CIT presents a challenging decision for physicians. While systemic tissue plasminogen activator (TPA) is an option, intracranial hemorrhage and distal embolization of the clot are significant limitations. Percutaneous options avoid cardiopulmonary bypass and the high bleeding risks associated with surgical thrombectomy and systemic TPA.³ The FLARE (FlowTrieve Pulmonary Embolectomy Clinical Study) demonstrated the effectiveness and safety of the percutaneous therapy in pulmonary embolism.⁴ This, in combination with utilization of ultrasound guided (radiation free) aspiration of CIT, allows percutaneous mechanical thrombectomy therapies an attractive niche for CIT. This is important especially in the postoperative patient population, where thrombolysis and/or even simple therapeutic anticoagulation compounds the risks.

Similar to our patient, intermediate to higher risk PE patients present diagnostic and therapeutic dilemmas for physicians. While the extremes of acutely unstable patients warrant systemic thrombolytic therapy and low risk patients can be managed safely solely with anticoagulation, these intermediate to higher risk patients require thoughtful consideration and ideally, utilization of a multidisciplinary pulmonary embolism response team.⁵ Recent data increasingly support the safety and efficacy of large bore aspiration for acute thromboembolism.⁶ Wible et al.⁶ found up to a 100% technical success with the device and over 70% of patients required less oxygen following the procedure. They highlighted the low rate of adverse events (3.8%, mainly driven by respiratory deterioration) with zero device related complications, furthering the evidence for the utility of the device for acute thromboembolism.

CONCLUSIONS

Due to the limited literature regarding percutaneous extirpation of clot in transit, this dramatic case of hemodynamic and clinical improvement was presented. Several learning points are notable. Clot in transit creates a challenging therapeutic decision for physicians. Percutaneous mechanical thrombectomy has the potential to revolutionize the treatment of thromboembolism in transit and should continue to gain momentum given the safety and efficacy of the device.

REFERENCES

- 1 Verma I, Chang EY, Kumar G, Sachdeva R. Catheter directed embolectomy of right atrial clot in transit-A case series. *Catheter Cardiovasc Interv* 2021; 97(5):869-873. PMID: 33226187.
- 2 Abdel-hafez O, Salih M, Aloka F, Patel K. Intravascular ultrasound-guided mechanical thrombectomy using the INARI ClotTrieve device of an iatrogenic deep venous thrombosis. *BMJ Case Rep* 2020; 13(7):e235464. PMID: 32675124.
- 3 Giri J, Sista AK, Weinberg I, et al. Interventional therapies for acute pulmonary embolism: Current status and principles for the development of novel evidence: A scientific statement from the American Heart Association. *Circulation* 2019; e774-e801. PMID: 31585051.

⁴ Tu T, Toma C, Tapson VF, et al. A prospective, single-arm, multicenter trial of catheter-directed mechanical thrombectomy for intermediate-risk acute pulmonary embolism: The FLARE study. *JACC Cardiovasc Interv* 2019; 12(9):859-869. PMID: 31072507.

⁵ Chaudhury P, Gadre SK, Schneider E, et al. Impact of multidisciplinary pulmonary embolism response team availability on management and outcomes. *Am J Cardiol* 2019; 124(9):1465-1469. PMID: 31495443.

⁶ Wible BC, Buckley JR, Cho KH, Bunte MC, Saucier NA, Borsa JJ. Safety and efficacy of acute pulmonary embolism treated via large-bore aspiration mechanical thrombectomy using the Inari FlowTrieve device. *J Vasc Interv Radiol* 2019; 30:1370-1375. PMID: 31375449.

Keywords: percutaneous aspiration thrombectomy, pulmonary embolism, deep vein thrombosis