

Adrenocortical Carcinoma as an Atypical Cause of Secondary Hypertension

Joy Ogundare, M.D.¹, Mark Meyer, M.D.¹, Mazin Al-Kasspoles, M.D.²

University of Kansas Medical Center, Kansas City, KS

¹Department of Family Medicine and Community Health

²Department of Surgery

Received Jan. 17, 2023; Accepted for publication March 3, 2023; Published online April 24, 2023
<https://doi.org/10.17161/kjm.voll6.19113>

INTRODUCTION

Adrenocortical carcinomas (ACC) are rare malignant tumors usually found incidentally on imaging.¹ Incidentalomas are adrenal tumors found incidentally on imaging. They are broken down into benign non-functioning adrenal adenomas, functional adrenal adenomas, and malignant tumours. Non-functioning adrenal adenomas account for about 80% adrenal incidentalomas. Functional adrenal adenomas account for 10-15% of adrenal incidentalomas, and are broken down into 5% pheochromocytoma, 5% cortisol producing, and 1% aldosterone producing. Finally, malignant tumours, such as primary adrenocortical carcinomas which is discussed in this case, account for less than 5% of adrenal incidentalomas.

Adrenocortical carcinomas usually are classified as functional (hormone secreting) or non-functional. Forty to seventy percent of ACCs are functional, of which almost 80% are associated with hypersecretion of glucocorticoids (Cushing syndrome).² Adrenocortical carcinomas only account for roughly 0.02% of all cancers³ and mean age of presentation is 40-50 years. Patients typically report symptoms of weight gain, striae, acne, hair, and cognitive changes. Clinical signs include hypertension, hyperglycemia, hyperlipidemia, and osteoporosis.⁴

CASE REPORT

A 27-year-old female presented in summer of 2022 for significant hypertension of unknown etiology. The previous year, she was found to have an elevated blood pressure (BP) of 140/110 mmHg but was lost to follow-up. During the current visit, the patient reported over the past six to seven months a 40 lb weight gain, bilateral lower extremity swelling, worsening acne, intermittent heart palpitations, and shortness of breath at rest and upon exertion.

On physical exam, blood pressure was checked twice and found to be elevated at 172/112 and 174/108 mmHg. Her abdomen was soft and non-tender, however, there was a large, somewhat mobile, palpable mass in the upper left abdomen. There was mild bilateral symmetrical lower extremity edema. The patient was sent home with amlodipine 2.5 mg daily and given instructions to monitor her BP daily.

Lab tests ordered included serum thyroid stimulating hormone and T4, complete blood count, comprehensive metabolic panel, and 24-hour urine metanephrines.

An abdominal ultrasound (Figure 1) demonstrated a large heterogeneous mass within the left upper quadrant in the region of the left adrenal gland, measuring roughly 15.4 x 11.8 x 14 cm. A CT of the abdomen (Figure 2) better characterized the mass to be lobulated, heterogeneous, and localized to the left adrenal gland, measuring 16.7 x 11 cm with several linear calcifications within the tumor. There was mass effect on multiple adjacent organs including the spleen, pancreas, and left kidney.

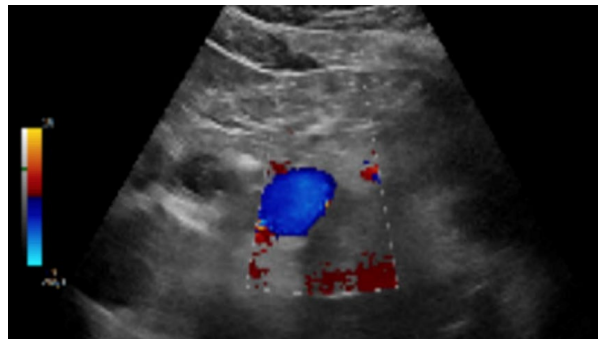


Figure 1. Ultrasound of left adrenal gland mass measured roughly 15.4 x 11.8 x 14 cm.

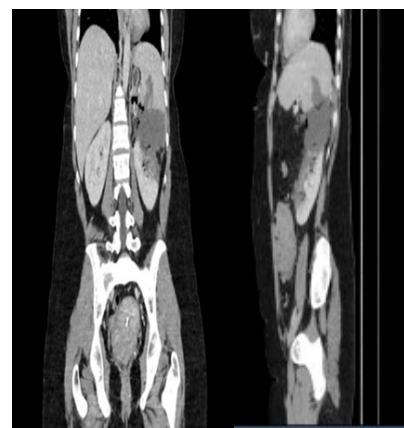


Figure 2. CT imaging of lobulated heterogeneous mass in the left adrenal gland was 16.7 x 11 cm in size and had several linear calcifications within the mass.

The patient's recorded daily blood pressure measurements were elevated at the 160s/110s mmHg. Amlodipine was increased to 5 mg. However, despite the medication change, she continued to have elevated BP readings and had systolic pressures intermittently as high as 180 mmHg. This worrisome clinical picture led to a hospital admission four days after her clinic appointment to workup the large adrenal mass that was associated with hypertensive urgency.

Upon admission, surgical oncology and endocrinology were consulted. An MRI demonstrated the large adrenal mass seen in CT. To rule out pheochromocytoma definitively, 24-hour urine metanephrines, a by-product of catecholamines, and serum catecholamines were ordered.

The patient was treated with phenoxybenzamine prophylactically in case the mass was a pheochromocytoma, for which the patient would have required alpha blockade for 10-14 days prior to surgery. However, serum catecholamine labs and 24-hour urine metanephrine test were negative thus pheochromocytoma was ruled out, and phenoxybenzamine was tapered off. AM cortisol, adrenocorticotropic hormone (ACTH), dehydroepiandrosterone sulfate (DHEA-S), and renin/aldosterone were ordered to workup possible DHEA-S-secreting adenoma vs. carcinoma. DHEA-S was elevated at 592 µg/dL and ACTH was suppressed due to cortisol production pointing toward Cushing syndrome.

During her admission, the patient had elevated heart rates up

to the 130s bpm and continued to have blood pressures of 150-160 mmHg systolic prior to surgery, thus losartan 25 mg daily was added. Since lab results ruled out a pheochromocytoma and were consistent with cortisol secreting tumor, the patient was scheduled by surgical oncology for an open adrenalectomy. Due to signs of adrenal insufficiency, the patient was administered stress dose steroids of 50 mg hydrocortisone three times daily prior to surgery. A large 25 x 20 cm adrenal mass, which was attached to the inferior vena cava with extensive neovascularization, was grossly and completely resected (Figure 3).

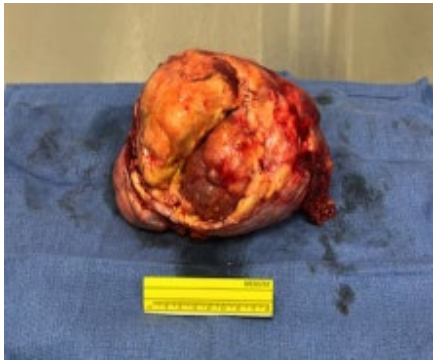

Figure 3. The adrenal carcinoma was resected.

After the adrenal mass was removed, the patient's blood pressure greatly improved to (119-141)/(62-98) mmHg. Amlodipine 5 mg and losartan 25 mg were continued. The patient remained on stress dose steroids with the plan to administer a long-term taper as an outpatient by the endocrinology service, which continued to follow the patient in their clinic.

Pathology slides of the adrenal mass utilized H&E, SF-1, and Ki67 stains (Figure 4). H&E stains helped to differentiate between rapidly dividing cancer cells and normal tissue. Normal tissue stains pink and cancerous tissue stains blue. Figure 4 of the patient's adrenal mass was predominately blue staining confirming the presence of carcinoma. Increased SF-1 and Ki67 staining further supported the diagnosis of an adrenal cortico-carcinoma⁵ and were evident by dark staining in Figure 5. Final pathology was consistent with Stage III (pT3, pNX, cM0) adrenocortical carcinoma.

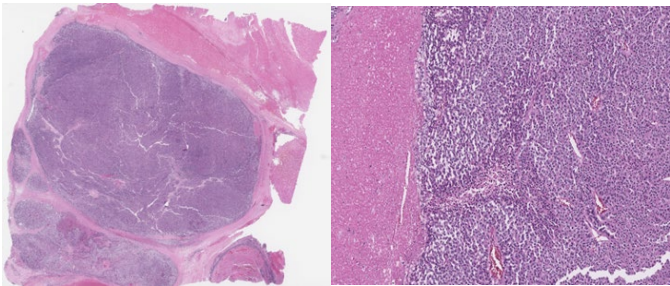


Figure 4. Histology slides of the patient's adrenal mass: H&E stain (left) and H&E x 10 magnification (right).

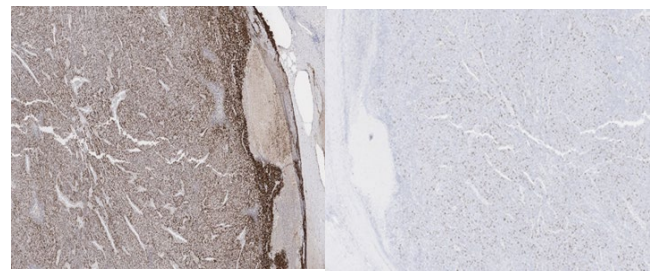


Figure 5. Histology slides of the patient's adrenal mass: SF-1 stain (left) and Ki67 stain (right).

A few weeks after discharge, the patient presented to the emergency room with abdominal pain, a white blood count of $15.3 \times 10^9/L$ and elevated creatinine. A CT of the abdomen/pelvis demonstrated splenic fossa abscess. The patient was admitted for placement of an interventional radiology drain, which was left in place upon discharge and removed two weeks later. As an outpatient, the patient was referred to oncology to initiate mitotane chemotherapy specifically for adrenocortical carcinoma. Furthermore, the patient was referred to genetic counselling to test for Li Faumeni, Lynch, and other hereditary syndromes/mutations.

Repeat imaging with PET/CT scans demonstrated multiple hypermetabolic liver masses, consistent with blood-borne distant metastases, and soft tissue masses between stomach and spleen, concerning for locoregional recurrence. Thus, the malignancy had progressed to stage IV (cT3, cNX, cM1). Chemotherapy with Etoposide + Doxorubicin + Cisplatin was initiated, and daily mitotane was continued. Treatment with steroids was continued instead of tapered off as originally planned due to the patient's worsening disease. In addition, the patient met with the radiation oncology service, which decided to delay radiation therapy until the disease burden decreased.

DISCUSSION

Adrenocortical carcinoma is an extremely rare cancer with a poor prognosis. According to Keskin et al.⁶, in patients without evidence of metastatic disease, five-year survival rate is approximately 50% with complete resection. Five-year survival rate for patients with distant metastases ranges from 0 to 11.5%. The mean survival rate for patients with stage I–II, stage III and stage IV disease were 61, 32, and 5 months, respectively.

The patient in this report was a unique case because her persistently elevated blood pressure and Cushing's syndrome presentation led to further workup and confirmation by CT, whereas most of the literature described an incidental finding of adrenal mass on imaging.⁴ Furthermore, the patient was only 27 years old, whereas an adrenocortical carcinoma typically is diagnosed in individuals less than 5 or greater than 40 years old.³

This case demonstrated the importance of multi-specialty involvement in the work-up and treatment of patients with adrenocortical carcinoma. Surgical oncology consultation and resection with negative margins is the single most important prognostic factor for survival in patients with ACC. Open adrenalectomy is the gold standard surgical approach for confirmed or highly suspected ACC.⁷ The tumor in this report was peeled off the inferior vena cava, thus microscopic residual disease likely was present after the resection despite negative margins on pathology.

Pathology confirms diagnosis of ACC by histopathological analysis of the adrenal mass. According to Ahmed et al.⁵, Ki67 is one of the most important histological markers in differentiating benign from malignant adrenal lesions. Lesions with Ki67 index greater than 5% are likely to be malignant. Figure 5 showed a Ki67 stained specimen from this case and the patient's Ki67 index was greater than 5%, as demonstrated by multiple dark stainings. Furthermore, tumors with less than 10% Ki67 have better outcomes than those with greater than 10% Ki67. Figure 5 demonstrated SF-1 protein staining which helped to confirm the adrenocortical origin of an adrenal mass. Increased SF-1 staining is correlated significantly with poor clinical outcome.⁸ Finally, a common stain done by pathology is the H&E stain where the cytoplasm stains pink and the cell nuclei stains blue. Malignant tissue will have an abundance of blue staining tissue due to the hyperactivity of cancer cells dividing, which is demonstrated in figure 4.

Once diagnosis is confirmed, follow-up with oncology and initiation of chemotherapy is necessary. According to Tang et al.², mitotane is a daily chemotherapy that significantly decreases recurrence rate and mortality after resection of ACC in patients without distant metastasis. Adding EDP (etoposide, doxorubicin, and cisplatin) improves progression-free survival if distant metastasis is present.⁶

In addition to treatment, genetic counselling is beneficial. According to Ahmed et al.⁵, most ACCs develop sporadically but some were associated with familial cancer syndromes like Li-Fraumeni, Beckwith-Wiedemann (BWS), and Lynch Syndromes (LS). Interestingly, screening for patients diagnosed with Li-Fraumeni syndrome involves abdominal ultrasounds every four months until the age of 18. However, in patients with LS or BWS, there is no routine screening for ACC due to the rarity of the condition. The Wingless iNTEgration (WNT) signaling pathway is a common pathway involved in the development of ACC. It is involved in cell growth and renewal, but dysregulation of this pathway leads to oncogenesis in tissues like the adrenal gland. C-MET is a tyrosine kinase that is overexpressed in ACC, and it is hypothesized that this occurs as a resistance mechanism to radiation and chemotherapy.

CONCLUSIONS

Adrenocortical carcinoma is typically an incidentaloma found on imaging but also may be a rare cause of secondary hypertension. The patient in this case report, initially presented with hypertension as her only finding more than a year before her follow-up presentation. This case is a cautionary commentary on the importance of working up other hypertensive causes in otherwise healthy young adults. It may be beneficial to include a workup for adrenal pathologies as part of secondary hypertensive workup to prevent delayed diagnosis, and subsequent disease burden.

If diagnosed with ACC, surgery and chemotherapy are the mainstay treatment and lead to progression-free years of disease. In addition, genetic counselling is necessary to determine the presence of a genetic syndrome. Future medical advances should be directed at targeting oncogenes like C-MET or the WNT signaling pathway in patients to treat and improve tumor response.

ACKNOWLEDGEMENTS

The authors thank Issa Al-Kharouf, M.D., Todd Stevens, M.D., Mazin Al-Kasspooles, M.D., Hannah Swagerty, M.D., and the Family Medicine team that took care of patient both inpatient and outpatient.

REFERENCES

- 1 Willatt JM, Francis IR. Radiologic evaluation of incidentally discovered adrenal masses. *Am Fam Physician* 2010; 81(11):1361-1366. PMID: 20521756.
- 2 Tang Y, Liu Z, Zou Z, Liange J, Lu Y, Zhu Y. Benefits of adjuvant mitotane after resection of adrenocortical carcinoma: A systemic review and meta-analysis. *BioMed Res Int* 2018; 2018:9362108. PMID: 29967789.
- 3 Roman S. Adrenocortical carcinoma. *Curr Opin Oncol* 2006; 18(1):36-42. PMID: 16357562.
- 4 Gendy R, Rashid P. Incidental adrenal masses - A primary care approach. *Aust Fam Physician* 2017; 46(6):385-390. PMID: 28609594.
- 5 Ahmed AA, Thomas AJ, Ganeshan DM, et al. Adrenal cortical carcinoma: Pathology, genomics, prognosis, imaging features, and mimics with impact on management. *Abdom Radiol (NY)* 2020; 45(4):945-963. PMID: 31894378.
- 6 Keskin S, Taş F, Vatansever S. Adrenocortical carcinoma: Clinicopathological features, prognostic factors and outcome. *Urol Int* 2013; 90(4):435-438. PMID: 23343838.
- 7 Sinclair TJ, Gillis A, Alobuia WM, Wild H, Kebebew E. Surgery for adrenocortical carcinoma: When and how? *Best Pract Res Clin Endocrinol Metab* 2020; 34(3):101408. PMID: 32265101.
- 8 Sbiera S, Schmull S, Assie G, et al. High diagnostic and prognostic value of steroidogenic factor-1 expression in adrenal tumors. *J Clin Endocrinol Metab* 2010; 95(10):E161-171. PMID: 20660055.

Keywords: hypertension, Cushing Syndrome, adrenocortical carcinoma, adrenalectomy