

Amyotrophic lateral sclerosis and spinocerebellar ataxia type 2: A familial case report

Shirani Rajan MD MSPH,
Maysen Mesaros MS CGC, Mohamed Menofy MD,
Katherine Ruzhansky MD MS

Medical University of South Carolina Department of
Neurology, Charleston, USA

Introduction

While separate and phenotypically distinct diseases, spinocerebellar ataxia type 2 (SCA2) and amyotrophic lateral sclerosis (ALS) share a genetic association via a trinucleotide (CAG) repeat expansion in the *ATXN2* gene [1,2]. While ubiquitin-positive cytoplasmic inclusions of trans-activate response DNA-binding protein (TARDBP or TDP-43) are known to be pathognomonic for ALS, these TDP-43 inclusions are also seen in the cytoplasm of motor neurons in SCA2. This elucidates an interconnected pathway of gene overexpression and protein toxicity [2,3]. Full expansion is associated with an increased presence of TDP-43 inclusions in the cytoplasm of degenerating neurons [4].

While the genetic association between ALS and SCA2 via the *ATXN2* gene is well established, there are few reports demonstrating intrafamilial phenotypic variability of *ATXN2* mutations. Here we report a family with separate and distinct phenotypes via repeat expansions in *ATXN2*, whose presentations do not align with their expected phenotypes based on CAG repeat size.

Case Description

A 36-year-old female presented to Neuromuscular Neurology clinic with painless bilateral arm weakness for 7 months. Physical examination revealed tongue fasciculations, and mild dysarthria on cranial nerve testing. Upper extremity strength showed 3/5 strength (Muscle Power Assessment MRC Scale) in the right deltoid, 4/5 strength in the right biceps, triceps, wrist flexors, extensors and abductor pollicis brevis (APB), and 1/5 strength in the right first dorsal interosseous (FDI) muscle. Left upper extremity strength testing showed 4/5 strength in the deltoid, 4+/5 in the biceps, triceps, wrist flexors, extensors, APB, and 1/5 strength in the FDI. Lower extremity strength testing was 5/5 throughout on initial examination. Finger contractures were noted. Sensory examination was normal. Reflex testing showed 2+ reflexes throughout, which were

deemed pathologic in the upper extremities for degree of weakness. There was a positive right pectoralis, right Hoffmann, and mute toes. Cerebellar testing was not done on initial assessment, and as the patient progressed became not possible due to weakness. Diagnostic evaluation included MRI of the brain and cervical spine, which were normal. Laboratory work-up included normal thyroid function tests, normal serum angiotensin-converting enzyme level, absent monoclonal on serum protein electrophoresis with immunofixation, serum creatinine kinase of 334 U/L, normal serum copper and paraneoplastic panels. Electrodiagnostic testing showed evidence of a widespread neurogenic process with active and chronic denervation seen in the tested muscles of the right arm, leg and trapezius. Subtle sensory nerve abnormalities in the right median, ulnar, radial and sural nerves were of unclear clinical significance. The patient underwent genetic testing which included *SOD1* gene sequencing and *C9orf72* plus *ATXN2* repeat expansion analysis. Her *SOD1* sequencing was normal, as well as her *C9orf72* analysis which revealed G4C2 repeat sizes of 6 and 7. Her *ATXN2* analysis revealed a heterozygous, pathogenic repeat expansion of 40 CAG repeats. Based on her clinical symptomatology, work-up, and electrodiagnostic testing, a diagnosis of ALS was made. Over the next year, the weakness progressed to include dysarthria, dysphagia, leg weakness with loss of ambulation, and respiratory failure. When still ambulatory, she was noted to have wide-based gait, which might have been related to a lack of arm movement. She progressed to quadriplegia and died at age 39.

Family history revealed olivopontocerebellar degeneration (OPCD) and SCA type 2 (SCA2) in her brother, diagnosed at 16. He presented with symptoms such as falls and dysarthria and became wheelchair bound. Per chart review provided by the patient's mother, the brother's physical exam showed horizontal nystagmus, right nasolabial fold flattening, leftward tongue deviation with 3+ reflexes at the ankle and knees, and bilateral extensor response. He was noted to have wide based stance, ataxic gait, and positive Romberg. His brain MRI showed olivopontocerebellar atrophy. He died 9 years post-diagnosis and 13 years prior to the presentation of our patient. Our patient's father had a reported history of gait imbalance, ataxia, tremor, dysarthria, and a possible prior diagnosis of OPCD. He died at age 50 of an unknown cardiac condition. Our patient's paternal aunt was also suspected to have SCA. There was an additional report of ALS on the paternal side although it was unclear who was affected. The pattern of familial inheritance is regarded as autosomal dominant (Figure 1).

Figure 1. Family Pedigree

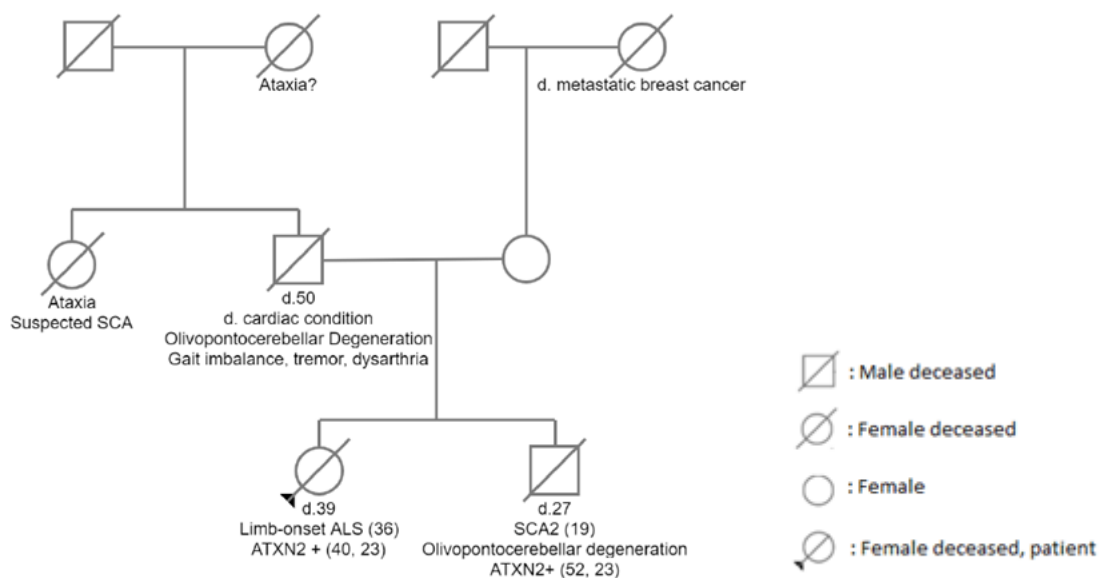
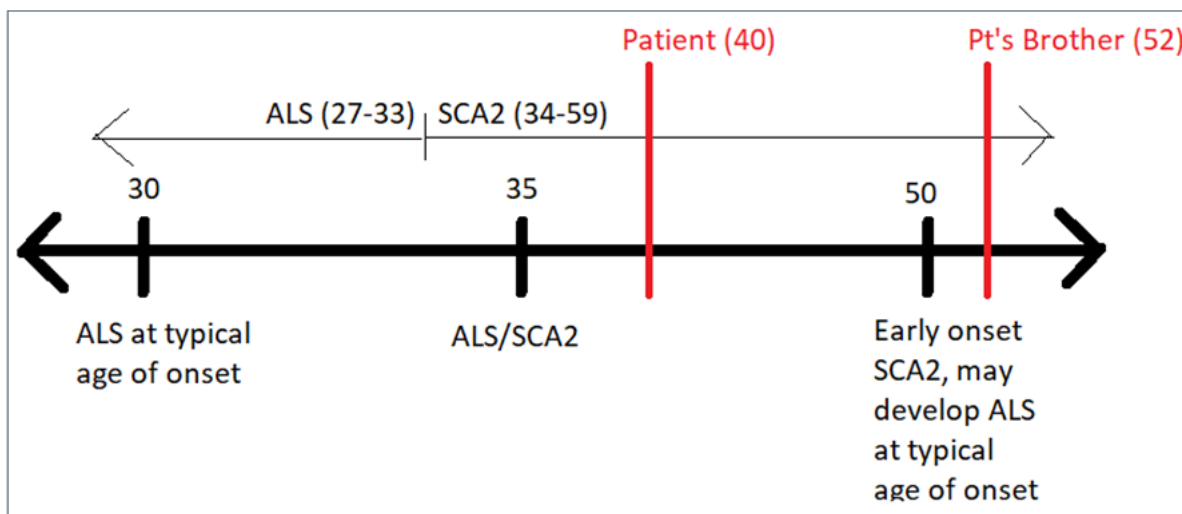


Figure 2. Variability of ALS and SCA2 by Expansion length



Patient: ATXN2 Positive (Allele 1:40 repeats, Allele 2: 23 repeats), Patient's brother: ATXN2 Positive (Allele 1: 23 repeats, Allele 2: 52 repeats). Amyotrophic Lateral Sclerosis (ALS), Spinocerebellar Ataxia Type 2 (SCA2)

Discussion

The length of CAG repeat expansion in the *ATXN2* gene is directly related to the age of onset and severity of SCA2. There is also evidence to suggest that CAG repeat length correlates with the expected phenotype (ALS vs. SCA2). Development of SCA2 is typically associated with CAG repeat sizes of 33 or greater, while the development of ALS is typically associated with an intermediate length of CAG repeat expansion (27-33) [1,5]. ALS and SCA2 share a genetic basis consisting of expanded CAG repeats in the *ATXN2* gene and TDP-43-positive neuronal cytoplasmic inclusions, but few cases of families affected by both diseases have been reported [3,6]. This case documents a patient who was diagnosed with ALS without manifested signs of spinocerebellar ataxia despite having full CAG repeat expansion 40/23, and a sibling with SCA2 (Figure 2). Prior reports proposed that SCA2 onset age is inversely proportional to expansion length [1]. In this familial case, this is less relevant to the patient, but it does apply to her sibling. The number of CAA interruptions to the CAG expansion has been shown to be inversely associated with the age of ALS onset in patients with an average repeat length of ~27 [1,7]. In this case, the 40-repeat expansion bodes an increased risk of SCA2 and not necessarily ALS. Our patient's development of early-onset ALS may be explained at least partly by CAA interruptions. As CAA interruptions increase the stability of CAG expansion [1], thus expressivity may be influenced by the degree of CAA codon interruption to the CAG repeat. However, CAA interruption data was unavailable for review.

Despite attempts to characterize a distinction between disease entities by mutation history, this case highlights heterogeneity in the genetic background and development of ALS versus SCA2. Understanding the genotype-phenotype correlation of *ATXN2* mutations has implications for neuromuscular and movement disorder neurologists and genetic counselors, specifically in ordering appropriate genetic testing, providing accurate risk assessment for relatives, and providing access to genetically targeted therapies. Identification of ataxia, olivopontocerebellar atrophy, or Parkinsonian disease in the family history of an individual with ALS warrants analysis of *ATXN2*. When providing risk assessment for family members at risk of

an *ATXN2* repeat expansion, it is crucial to consider and advise that family members may present differently based on repeat size and degree of CAA codon interruption.

Corresponding Author

Maysen Mesaros, MS, CGC
mesaros@musc.edu

References:

1. Ghahremani Nezhad H, Franklin JP, Alix JJP, et al. Simultaneous ALS and SCA2 associated with an intermediate-length *ATXN2* CAG-repeat expansion. *Amyotroph Lateral Scler Frontotemporal Degener.* 2021;22(7-8):579-582. doi:10.1080/2167842.1.2020.1853172
2. Gispert S, Kurz A, Waibel S, et al. The modulation of Amyotrophic Lateral Sclerosis risk by ataxin-2 intermediate polyglutamine expansions is a specific effect. *Neurobiol Dis.* 2012;45(1):356-361. doi:10.1016/j.nbd.2011.08.0213.
3. Laffita-Mesa JM, Paucar M, Svenningsson P. Ataxin-2 gene: a powerful modulator of neurological disorders. *Curr Opin Neurol.* 2021;34(4):578-588. doi:10.1097/WCO.0000000000000959
4. Van Damme P, Veldink JH, van Blitterswijk M, et al. Expanded *ATXN2* CAG repeat size in ALS identifies genetic overlap between ALS and SCA2. *Neurology.* 2011;76(24):2066-2072. doi:10.1212/WNL.0b013e31821f445b
5. Antenora A, Rinaldi C, Roca A, et al. The Multiple Faces of Spinocerebellar Ataxia type 2. *Ann Clin Transl Neurol.* 2017;4(9):687-695. Published 2017 Aug 10. doi:10.1002/acn3.437
6. Tazen S, Figueroa K, Kwan JY, et al. Amyotrophic lateral sclerosis and spinocerebellar ataxia type 2 in a family with full CAG repeat expansions of *ATXN2*. *JAMA Neurol.* 2013;70(10):1302-1304. doi:10.1001/jamaneurol.2013.443
7. Corrado L, Mazzini L, Oggioni GD, et al. *ATXN-2* CAG repeat expansions are interrupted in ALS patients. *Hum Genet.* 2011;130(4):575-580. doi:10.1007/s00439-011-1000-2